



## Laryngeal chondrosarcoma (case report)

Abdurakhmanov O.B.<sup>1</sup>,

Khudayorov M.S.<sup>2</sup>,

Soatov U.A.<sup>3</sup>

Yuldashev L.T.<sup>2</sup>

<sup>1</sup> «Akfa Medline University hospital», Tashkent, Uzbekistan

<sup>2</sup> Tashkent State Medical University, Tashkent, Uzbekistan

<sup>3</sup> Tashkent State Medical University Termez branch, Uzbekistan

<sup>2</sup> Tashkent State Medical University, Tashkent, Uzbekistan

### ABSTRACT

**Introduction:** Chondrosarcoma of the larynx is a rare type of laryngeal tumor that is often underestimated by patients and diagnosed at late stages of the disease. Clinical, histological, and radiological correlation is necessary for the diagnosis of chondrosarcoma of the larynx. Although the prognosis is relatively favorable, conservative surgical excision with negative margins is recommended. This article describes a case of chondrosarcoma of the larynx in a patient who required total laryngectomy.

**Case report:** A 68-year-old male chronic smoker from Surkhandarya region presented with complaints of progressive dysphonia, hoarseness, airway obstruction, and dysphagia, and was admitted to the «Happy Life Medical» clinic in Tashkent in May 2021. After a series of investigations, a laryngeal tumor was detected, and surgical intervention in the form of laryngectomy was carried out as planned. After histological examination of the surgical material, the diagnosis of chondrosarcoma of the larynx was established.

**Discussion:** Chondrosarcoma of the larynx is a rare disease that can be difficult to diagnose visually. Tissue samples show smooth, lobulated, and translucent areas, and the diagnosis is based on the cartilaginous criteria of malignant neoplasms. Chondrosarcomas of the larynx may be associated with benign chondroma in 62% of cases. Surgical intervention is the initial treatment, and therapeutic methods include CO2 laser resection, hemircoidectomy, or hemilaryngectomy. Tumor recurrence is observed in 18-40% of patients, but the long-term prognosis of chondrosarcoma of the larynx is good, with a 10-year survival rate of up to 95%. Metastases develop rarely and only in 10% of cases. Radiation therapy remains a controversial treatment method, and chemotherapy is not therapeutically effective.

**Conclusion:** Surgical treatment of chondrosarcoma of the larynx is the most effective as it is relatively insensitive to chemotherapy and radiation therapy. CT is an integral radiological diagnostic method for establishing the diagnosis and determining the scope of the operation.

### Keywords:

chondrosarcoma of the larynx, laryngectomy, tracheostomy, cryoidectomy, treatment

### Introduction

Laryngeal chondrosarcoma is a rare tumor that accounts for about 1% of all laryngeal neoplasms [2]. It was first described by Travers in 1816 [3], but the term chondrosarcoma on

this site was introduced only in 1935 [4]. Since 1816, about 300 observations of laryngeal chondrosarcoma have been described in literary sources. Men aged 50-70 years are most often ill. In 70% of cases, the cricoid

cartilage is affected, in 20% — the thyroid cartilage, less often the tumors are localized in the region of the arytenoid cartilage — 10% [4].

There is a distinction between primary and secondary laryngeal chondrosarcoma. Primary chondrosarcoma can develop from preserved embryonic cartilage islets or from

undifferentiated multipotent cells of mesenchymal origin. Secondary chondrosarcoma develops as a result of chondroma malignancy, osteochondroma. A number of authors describe the development of a tumor against the background of multiple injuries and operations.

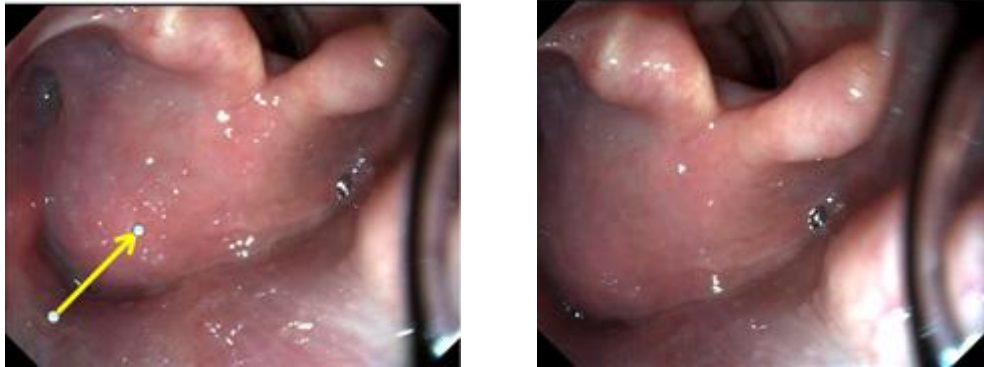


Fig 1. Direct laryngoscopy revealed a left paramedian vocal cord gap and a submucosal mass involving the vocal cord, surrounded by intact mucosa and a non-mobile ipsilateral arytenoid cartilage (arrow).

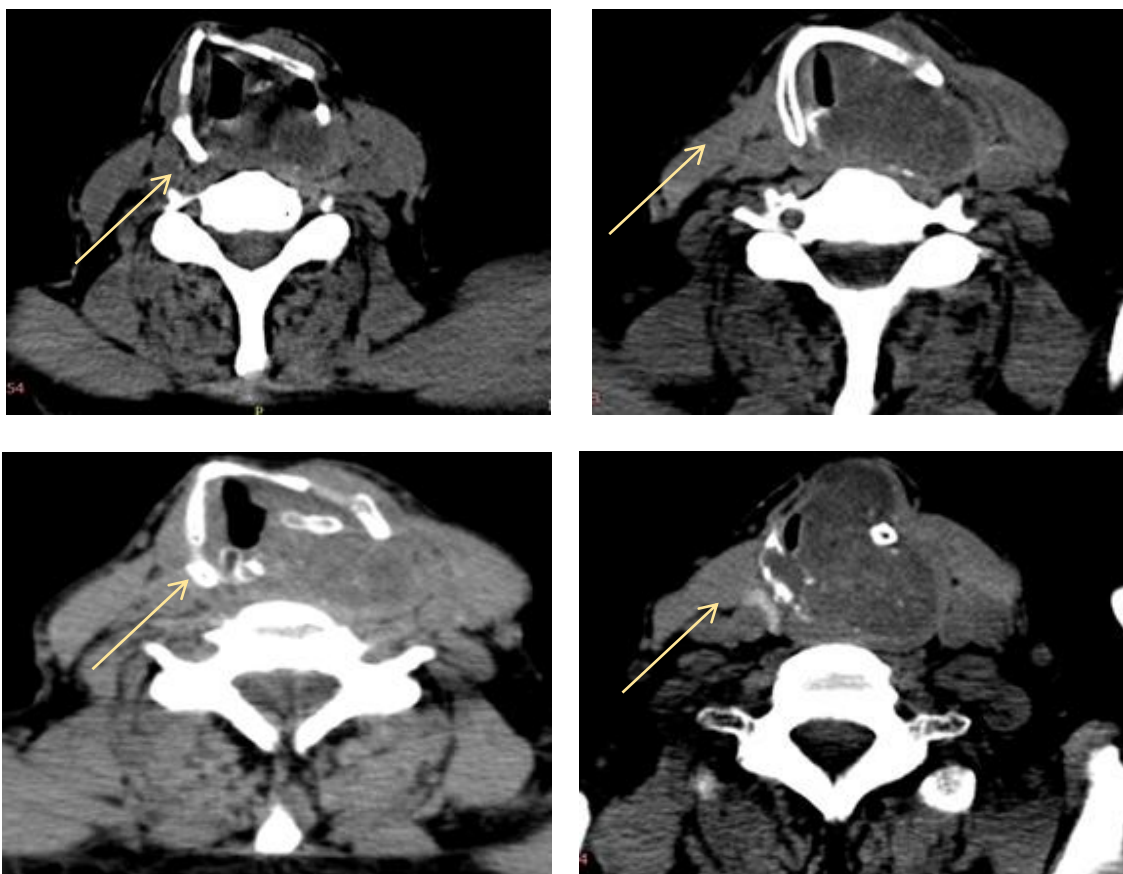


Fig. 2. The patient's neck CT scan is an axial projection. The larynx demonstrates a volumetric formation measuring up to 4.8x4.8x4.1 cm, +33+46 HU, with a heterogeneous structure.

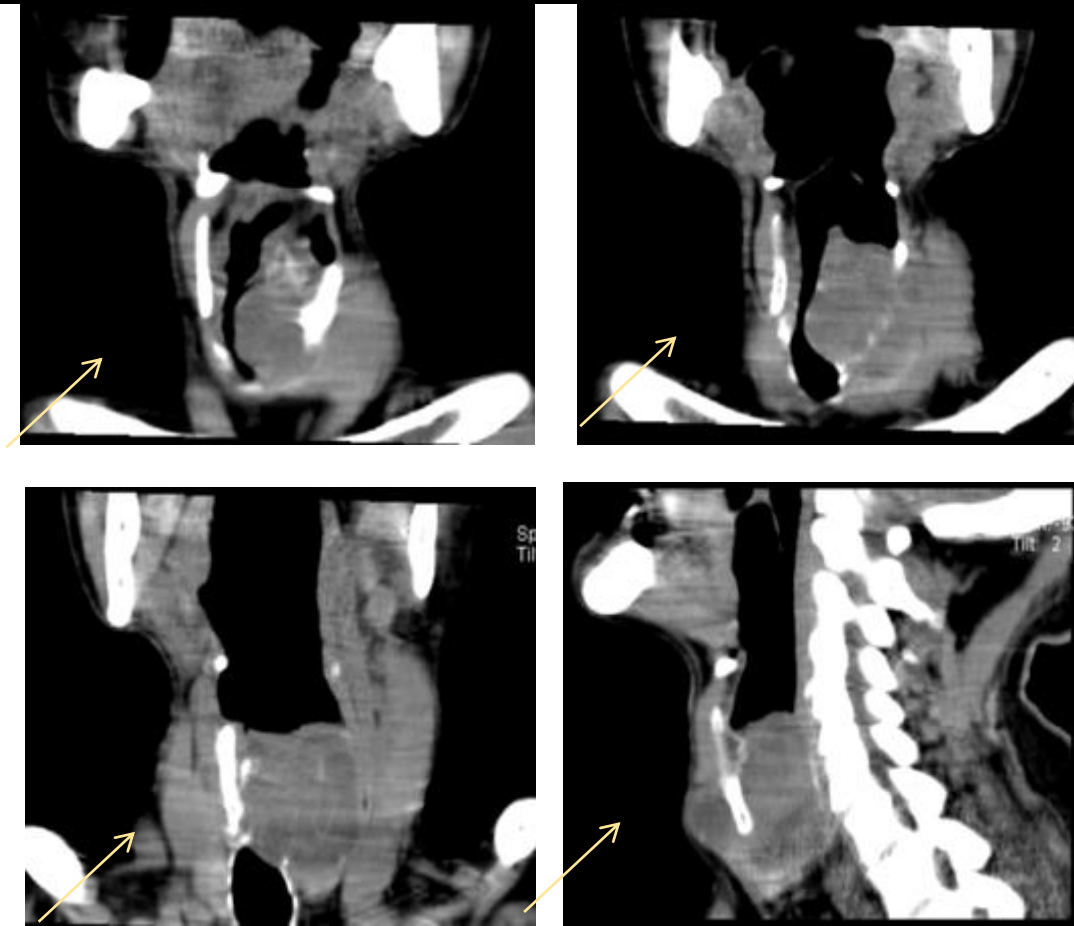


Fig. 3. The patient's neck CT scan includes both a frontal and sagittal projection. In the larynx projection, a volumetric formation with dimensions of up to 4.8x4.8x4.1 cm, +33+46 HU, and a heterogeneous structure is identified.

Early diagnosis of laryngeal chondrosarcoma is difficult due to the fact that patients often underestimate their feelings and consult a doctor at stages III-IV of the disease.

The diagnosis requires clinical, histological, and radiological correlation. It usually shows a low histology with a rather sluggish progression and a relatively low probability of metastatic potential or recurrence. For this reason, conservative surgical excision with negative margins is recommended [5]. We present a case of laryngeal chondrosarcoma from cricoid cartilage in a patient who had hoarseness of voice, shortness of breath, and computed tomography of the cervical region, which revealed a large tumor requiring total laryngectomy.

In May 2021, a 68-year-old patient, a resident of Surkhandarya region, a chronic smoker, had a history of progressive dysphonia, hoarseness, airway obstruction and

worsening dysphagia during a 12-month period with a diagnosis of laryngeal chondrosarcoma, in the ENT clinic "Happy life medical" in Tashkent. From the patient's medical history, hoarseness has been observed since the summer of 2020. I didn't go to the doctors. In January 2021, complaints of difficulty breathing through the natural respiratory tract and shortness of breath appeared and began to increase steadily. In May, with a diagnosis of laryngeal stenosis, he was hospitalized in the ENT department of the Happy Life medical clinic for an urgent tracheostomy operation. After a series of examinations, a laryngeal tumor was detected. Direct fibrolaryngoscopy (05/15/2021): a large tumor is detected, occupying the entire lumen of the larynx, starting from its vestibular region. It is impossible to determine the tumor growth zone. The mucous membrane above the tumor is unchanged — pink, smooth, elastic.

Pear-shaped sinuses are not visualized (Fig.1). MSCT of the soft tissues of the neck (05/16/2021): on a series of computed tomograms in the laryngeal space on the left at the VC level of 5-6 vertebrae, a volumetric oedema is detected, growing into the surrounding soft tissues, with uneven, not clear contours, with total dimensions of 4.8x4.8x4.1 cm, +33+46 units. The formation extends beyond the lower edge of the thyroid cartilage and significantly narrows the lumen of the trachea (germination into their lumen is possible). Also, the formation is closely adjacent to the upper contour of the left lobe of the thyroid gland. The boundaries between oedema and the structures listed above are unclear. Adjacent sections of cartilage and bone structures — with signs of destruction. Conclusion: MSCT shows signs of a bulky formation in the laryngeal space on the left with spread to surrounding tissues (Fig.2).

Given the prevalence of the tumor, surgical intervention in the volume of laryngectomy was performed as planned. The formation is removed within healthy tissues.

The conclusion of the histological examination of the surgical material dated 05/24/2021: the nodular formation is represented by growths over a larger area of hyaline cartilage extending to adjacent skeletal muscles, the presence of isogenic groups of various sizes, nuclear polymorphism of chondrocytes, dystrophic changes in the matrix, inclusions of bone beams and foci of necrosis. Hyaline cartilage, consisting of lobules of binucleated chondrocytes with an increased ratio of nucleus to cytoplasm. No mitotic activity was detected. There was no evidence of a myxoid matrix or any areas of necrosis. Perifocally: marked inflammatory infiltration with a predominance of neutrophilic leukocytes. These results are diagnostic for high-grade laryngeal chondrosarcoma (grade 1 of 3).

The postoperative period was uneventful. The wound was healed by primary tension. The nasogastric tube was removed on the 14th day.

## Discussion

Laryngeal chondrosarcoma is a rare tumor that accounts for less than 1% of all sarcomas

in the body. The tumor most often arises from the cricoid cartilage and less often from the arytenoid and thyroid cartilages [6]. The etiology of laryngeal chondrosarcoma is inaccurate, but it appears to be the result of impaired ossification of the laryngeal cartilage [7]. Current data do not show a causal relationship with smoking or alcohol consumption [2]. The average age of diagnosis ranges from 60 to 64 years, with a predominance of men [8]. Symptoms vary depending on the location of the formation and include hoarseness of the voice (in most patients) caused by narrowing of the glottis and compression of the lower laryngeal nerves; shortness of breath and airway obstruction due to endolaryngeal growth; dysphagia due to extralaryngeal growth occurring in the posterior ring-shaped space; and formation (mass) neck due to a tumor lesion of the thyroid cartilage [7]. Imaging, including CT, MRI, or X-ray, plays an important role in the assumption of chondroid neoplasm. There is usually an extensive lesion with variable density and characteristic "popcorn" calcifications [2].

Laryngeal chondrosarcomas have a histologically low degree of malignancy, and imaging does not always unambiguously differentiate grade I chondrosarcoma from benign chondroma, knowing that these two lesions can be associated with 62% of cases [5]. Invasion of adjacent soft tissues or bone may be present. Macroscopically, the tumor ranges in size from less than 1 cm to 10 cm. The sample is often obtained fragmented, and it constantly shows smooth, lobed, and translucent areas of tissue [6]. The histological diagnosis is based on the criteria of cartilaginous malignancies described by Lichtenstein and Yalein in 1943 [9]. There are various degrees of chondrosarcoma: (I) Grade 1: similar to chondroma, more than two nuclei, absence of mitosis, some areas of calcification and bone tissue (70-80% of cases) (ii) Grade 2: increased number of cells, low nuclear/cytoplasmic state ratio, rare mitosis (10-15% of cases) (iii) Grade 3: multinucleated cells, increased nuclear/cytoplasmic ratio, large number of mitoses (5-10% of cases).

About 80% of laryngeal chondrosarcomas are classified as low-grade and usually differentiate well with a less aggressive type of chondrosarcoma compared to a more common form of chondrosarcoma. The initial treatment for laryngeal chondrosarcoma is surgical intervention [11]. The goal is to obtain a complete excision with negative margins [12]. In low-grade tumors, therapeutic methods include CO<sub>2</sub> laser resection, hemiricoidectomy, or hemilaryngectomy. In cases of high-grade tumors and relapses, total laryngectomy is the method of choice. When a cricoideotomy is performed, a laryngotracheal anastomosis is used to close the defect. The effectiveness of radiation therapy is still controversial. Chemotherapy is not of therapeutic interest [10]. According to the literature, the frequency of tumor recurrence ranges from 18 to 40% [2]. Nevertheless, the long-term prognosis of laryngeal chondrosarcoma is good (95%, 10-year survival) [2]. Metastatic potential is rare in grade 1 chondrosarcoma and is observed in only 10% of grade 2 lesions [4]. A study of 111 cases conducted by the Institute of Pathology of the Armed Forces showed that only 1.9% of cases developed metastases [6]. According to the results of our study, fifteen months later, the X-ray and clinical data showed no signs of recurrence or metastasis. For this reason, conservative therapy is the method of choice. Total laryngectomy is used for large tumors, the surgical intervention of which can cause destabilization of the cricoid cartilage [7].

## Conclusion

Laryngeal chondrosarcoma has slow and subtle symptoms. In this regard, patients go to doctors at later stages of the disease (stages III, IV). Since it is insensitive to chemo-radiation therapy, it is recommended to treat patients surgically in several volumes, depending on the prevalence of the disease. CT is an essential radiological diagnostic method for inserting a diagnosis and determining the scope of surgery.

## References

1. Mustafaev DM. Observation of chondrosarcoma of the larynx. *Bulletin of Otorhinolaryngology*.2018;83(2):54-55 (In Russ).
2. Buda RH, Feinmesser R, Shvero J. Chondrosarcoma of the larynx. *The Israel Medical Association Journal*. 2012;14(11):681–684.
3. Travers FA. Case of Ossification and Bony Growth of the Cartilages of the Larynx, Preventing Deglutition. *Journal of the Royal Society of Medicine*, 1816;7(1):150– 153.
4. New GB. Sarcoma of the larynx: report of two cases. *Archives of otolaryngology*, 1935;21(6):648–652.
5. Potochny EM, Huber AR. Laryngeal chondrosarcoma. *Head and Neck Pathology*. 2014;8(1):114–116.
6. Thompson LDR, Gannon FH. Chondrosarcoma of the larynx: a clinicopathologic study of 111 cases with a review of the literature. *American Journal of Surgical Pathology*. 2002;26(7):836–851.
7. Casiraghi O, Martinez-Madrigal F, Pineda-Daboin K, Mabelle G, Resta L, Luna MA. Chondroid tumors of the larynx: a clinicopathologic study of 19 cases, including two differentiated chondrosarcomas. *Annals of Diagnostic Pathology*. 2004;8(4):189–197.
8. Wang Q, Chen H, Zhou S. Chondrosarcoma of the larynx: report of two cases and review of the literature. *International Journal of Clinical and Experimental Pathology*.2015;8(2):2068–2073.
9. Lichtenstein L, Jaffe H. Chondrosarcoma of bone. *American Journal of Pathology*. 1943;19(4):553–589.
10. Rinaldo, Howard DJ, Ferlito A. Laryngeal chondrosarcoma: a 24-year experience at the Royal National Throat, Nose and Ear Hospital. *Acta Otolaryngologica*. 2000;120(6):680–688.
11. Gil Z, Fliss DM. Contemporary management of head and neck cancers. *The Israel Medical Association Journal*. 2009;11(5);:96–300.
12. Gripp S, Pape H, Schmitt G. Chondrosarcoma of the larynx: the role of

radiotherapy revisited – a case report and review of the literature. *Cancer*. 1998;82(1):108–115.