



Cognitive Sphere and Neuroimaging Changes in Patients with Vascular Debt: Parallels and Correlations

Muradimova A.R.,

Fergana Medical Institute of Public Health, Fergana, Uzbekistan

Roziqova G.A.

Fergana Medical Institute of Public Health, Fergana, Uzbekistan

ABSTRACT

Vascular dementia is not one disease, but several outlined syndromes, for which a common feature is the relationship between damage to the cerebral vessels and the development of symptoms of brain damage. Neuroimaging screening for COD involves magnetic resonance imaging (MRI) and a characteristic picture is the presence of leukoaraiosis. The aim of the study was to identify the presence of a parallel and correlation between the cognitive sphere and neuroimaging in patients with vascular dementia.

Keywords:

vascular dementia, neuroimaging, cognitive sphere, leukoaraiosis

Vascular dementia is a significant deterioration in human cognitive abilities caused by diseases of the vessels of the brain. According to some reports, the frequency of vascular dementia is up to 50% of all cases of dementia. Vascular dementia in its pure form accounts for approximately 10-15% of all cases of dementia in the elderly [1,2].

Clinical and pathogenetic ideas about vascular dementia for many years relied mainly on the concept of atherosclerotic dementia, the main mechanism of development of which was seen in the diffuse death of neurons ("secondary cerebral atrophy") due to ischemia caused by narrowing of the lumen of atherosclerotic cerebral vessels.

The presence of a vascular lesion of the brain is proved:

a) clinical data, such as an indication of acute or transient cerebrovascular accidents suffered by the patient and developed neurological disorders (hemiparesis, weakness of the lower branch of the facial nerve, hemianopsia, Babinsky's symptom, dysarthria). The presence of vascular dementia may be indicated by symptoms such as early onset gait

disorders (apraxic-atactic or parkinsonian), repeated spontaneous falls, pseudobulbar syndrome with emotional incontinence, violent crying and laughter, lack of urinary control;

b) on the basis of data from neuroimaging methods (CT/MRI), indicating the presence of single or multiple large or moderate infarcts in the cerebral cortex or subcortical region, or multiple lacunar infarcts in the subcortical region or in the white matter of the frontal regions, or a fairly common (not less than 1/4 of the area) decrease in the density of the subcortical white matter (leukoareosis (LA)). The absence of a vascular brain lesion on the tomogram testifies against the vascular etiology of dementia.

It should be emphasized that factors such as arterial hypertension or hypotension in old age, as well as data on the pathology (atherosclerosis) of cerebral vessels (according to the results of CT, Doppler and rheoencephalography, examination of the fundus) cannot be evidence of a vascular destructive brain lesion, since they serve only as factors for an increased risk of developing such a lesion, but by themselves do not indicate

it. Moreover, the complex of so-called cerebrovascular complaints (dizziness, headaches, syncopal episodes) cannot serve as the main evidence of the vascular genesis of dementia. Computed tomography indicators of vascular lesions of the brain are important only in conjunction with clinical data. This is especially true of leukoareosis, which can be detected in many brain diseases, including those accompanied by dementia [3].

The connection of dementia with cerebrovascular damage is confirmed by its development immediately after a stroke or after transient cerebrovascular accidents, with its relative stabilization without repeated cerebrovascular accidents, as well as by the coincidence of the psychopathological and neuropsychopathological structure of dementia with the localization of cerebrovascular damage, for example, a pseudoparalytic variant of dementia with the location of ischemic foci in the frontal region, the torpid variant with ischemic foci in the subcortical region, etc. [7,9]. The acute development of dementia without obvious neurological disorders, but in combination with the detection of vascular lesions of the brain by CT/MRI, also indicates with a high degree of probability its vascular nature [4,5,8]. At the same time, according to modern requirements for the diagnosis of dementia, especially in scientific research, its definitive diagnosis can be considered only on

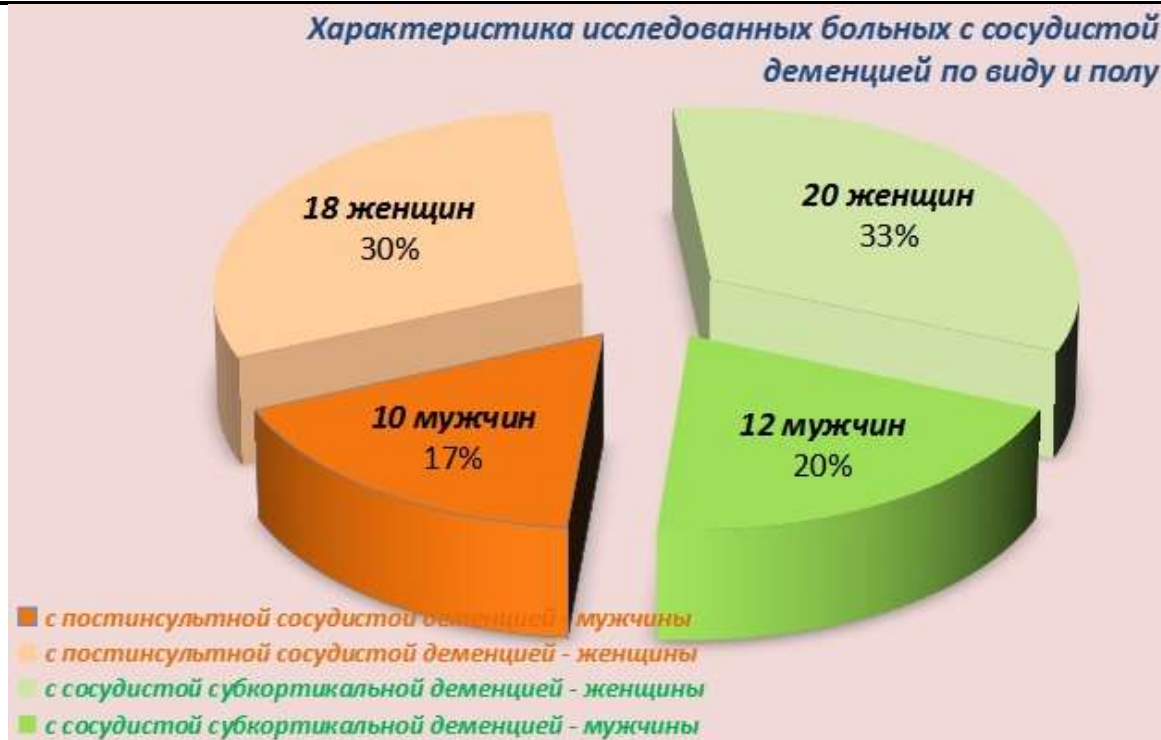the basis of its verification by autopsy data, including histological examination of the brain. Without these data, even in the presence of all these criteria, we can only talk about "probable" (probable) vascular dementia. In those cases when another (non-vascular) factor is not ruled out on the basis of clinical and instrumental data, a "possible" vascular dementia is stated [8].

In the last 10 years, thanks to the introduction of neuroimaging techniques and their combination with post-mortem morphometric study of the brain, there has been a rapid accumulation of knowledge about the structural, hemodynamic and metabolic characteristics of the brain in vascular dementia.

The purpose of the study: to identify the presence of parallels and correlations between the cognitive sphere and neuroimaging in patients with vascular dementia.

Materials and research methods. The study of patients was carried out in the Fergana Regional Psychoneurological Dispensary from 2020 to 2023. A total of 60 patients with mild to moderate vascular dementia were studied, of which 28 patients (10 men and 18 women, mean age 64.9 ± 4.6 years) with post-stroke vascular dementia, 32 patients (12 men and 20 women, mean age 70.75 ± 3.5 years) with vascular subcortical dementia (Fig. 1).

Figure 1. Characteristics of the studied patients with vascular dementia by type and sex



To objectify cognitive impairment in patients with dementia, a detailed neuropsychological examination was performed using psychometric scales. A set of psychometric tests on the MMSE scale was used to assess the severity of dementia and the presence of impairments to various cognitive functions. To identify relatively mild cognitive impairment in patients with vascular dementia, a modified Alzheimer's disease assessment scale was used, its cognitive part - Alzheimer's Disease Assessment Scale-cognitive subscale, ADAS-cog+ (Rosen WG, et al, 1984).

The generally accepted methods of variation statistics were used. The data were

processed by conventional statistical methods using standard statistical programs. The results are presented as $M (mean) \pm m$ (error) and μ (mean) $\pm \delta$ (standard deviation). The significance of statistical differences was assessed using Student's t-test. Differences were considered statistically significant at a significance level of at least 95% ($p < 0.05$).

Research results.

Comparative analysis of neuropsychological testing indicators, assessing cognitive impairment, revealed differences between groups of patients with vascular dementia (Table 1).

Table 1. Indicators of neuropsychological testing of patients with vascular dementia at the beginning of follow-up, $M \pm \delta$

Indicators on scales	Subcortical dementia (n= 32)			Post-stroke Dementia (n=28)		
	Mild degree (n =16)	Moderate (n =16)	R	Mild degree (n =15)	Moderate (n =13)	R
MMSE : • orientation	8.1±2.1	5.0±1.7	< 0.001	8.1±2.2	5.5±1.5	< 0.001

• <i>memorization</i>	2.9±0.8	2.6±0.5	< 0.01	2.8±1.1	2.9±1.15	> 0.05
• <i>attention and account</i>	2.3±0.7	1.5±0.5	< 0.001	2.5±0.8	1.1±0.6	< 0.001
• <i>reproduction of words</i>	1.6 ± 0.6	0.9 ± 0.5	< 0.0 01	1.5 ± 0.8	1.3 ± 0.75	> 0.05
• <i>repeated speech</i>	6.8 ± 1.5	5.0 ± 1.3	< 0.0 01	6.9 ± 1.7	5.7 ± 1.3	< 0.0 5
• <i>MMSE , total score</i>	21.8±3.1	15.8±2.3	< 0.001	21.9±3.4	16.5±2.6	< 0.001
• <i>ADAS - cog + , total score</i>	23.7±5.4	32.6±9.4	< 0.001	22.5±6.5	28.03±5.7	< 0.001

The study showed that among neuropsychological disorders in patients with vascular dementia, neurodynamic (activation) disorders prevailed, providing activation processes, both general and local, and regulatory disorders associated with impaired programming, regulation and control of mental activity. A comparative analysis of neuropsychological disorders in patients with varying degrees of severity of dementia showed that patients with moderate dementia have significantly more pronounced regulatory and operational disorders (associated with dysfunction in receiving, processing and storing information), as well as neurodynamic disorders.

The results of our study show that different types of periventricular and subcortical LA were identified in the group of patients with subcortical dementia . To determine the clinical significance of the regional distribution of PA, a comparative analysis of the parameters of neuropsychological testing in patients with PA of a certain localization was carried out.

In patients with LA localization predominantly in the anterior parts of the brain, mnesic disorders predominated, and impairments to executive functions and constructive praxis were also detected.

In patients with frontal LA, neurodynamic and mnesic disorders, disorders of verbal-logical thinking, dynamic

apraxia with impaired reciprocal coordination, and speech disorders, manifested by impoverishment of the structure of speech utterance, difficulties in choosing words, and a decrease in speech attention, predominated.

With localization of LA in the anterior and frontal parts of the brain, violations of regulatory and neurodynamic cognitive functions were noted. Operational disorders were found in the form of praxis disorders, manifested by difficulties in performing targeted actions and movements. In patients of this group, pronounced mnesic disorders were found. In the speech sphere, violations of the understanding of logical and grammatical structures, difficulties in choosing words, verbal paraphasias were revealed. Violations of executive functions and optical-spatial gnosis were revealed.

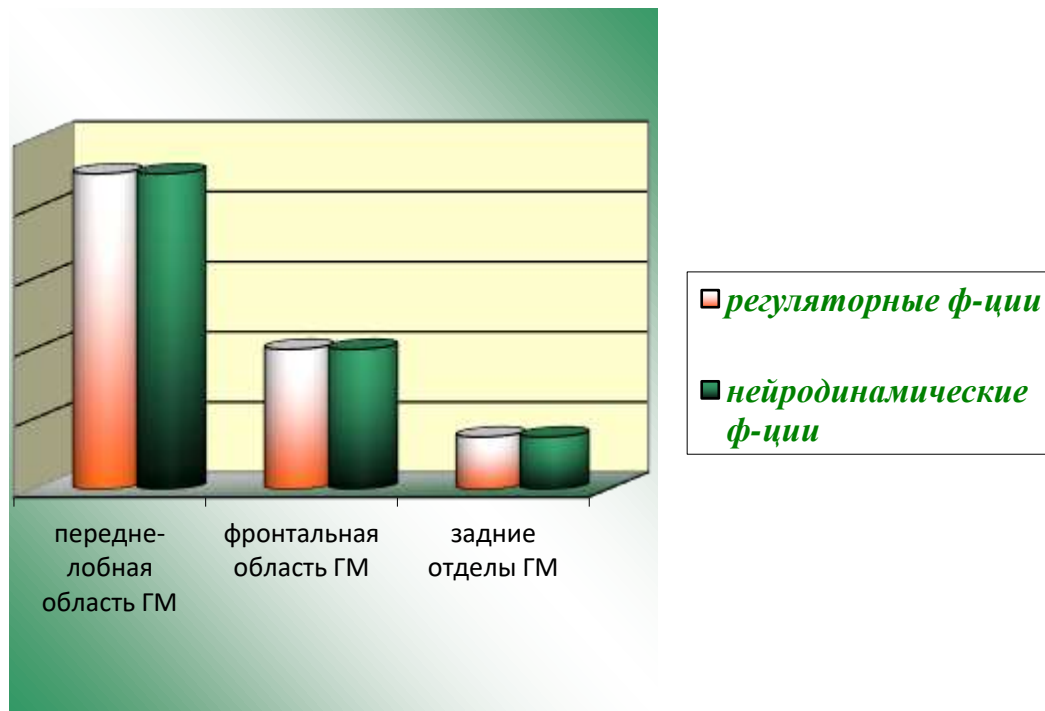
When LA was localized in the anterior, frontal, and posterior parts of the brain, mnesic and executive dysfunctions predominated. Operational disorders were manifested in the form of violations of the ideator praxis.

A comparative analysis of the results of neuropsychological testing in comparison with the regional distribution of leukoaraiosis showed that the regional distribution of leukoaraiosis is important in the development of cognitive impairment. The most pronounced changes are noted in the localization of leukoaraiosis in the anterior-frontal region of

the brain, while regulatory and neurodynamic functions are most disturbed. Somewhat less pronounced, but quite distinct cognitive impairments were also found in the frontal distribution of the LA. Subcortical LA,

predominantly located in the posterior regions of the brain, had a lesser effect on cognitive functions in patients with subcortical dementia (Figure 2).

Figure 2. Comparative analysis of the results of neuropsychological testing in comparison with the regional distribution of leukoaraiosis in subcortical vascular dementia



To determine the clinical significance of subcortical PA lesions located in certain areas of the brain, a comparative analysis of the parameters of neuropsychological testing was carried out in patients with unilateral and bilateral lesions of a certain localization (Figure 3).

A comparative neuropsychological study showed that in patients with predominant localization of subcortical PA foci *in the globus pallidus* in the left hemisphere, neurodynamic disorders predominated in the form of reduced concentration, impaired verbal-logical thinking, and impaired executive functions. In patients with right-sided localization of subcortical PA foci in the same area, mnemonic disorders and disorders of optical-spatial gnosis were more often found. Bilateral lesions of the globus pallidus were accompanied by severe neurodynamic disorders, visual attention and executive functions disorders were revealed.

In patients with predominant localization of subcortical LA foci *in the shell region* in the left hemisphere, mnemonic disorders predominated in the form of impaired word reproduction and visual attention disorders. In patients with bilateral localization of subcortical LA foci in the same area, mnemonic disorders were more often found in the form of a decrease in the activity, strength and selectivity of memorizing words, disturbances in spatial functions and optical-spatial gnosis.

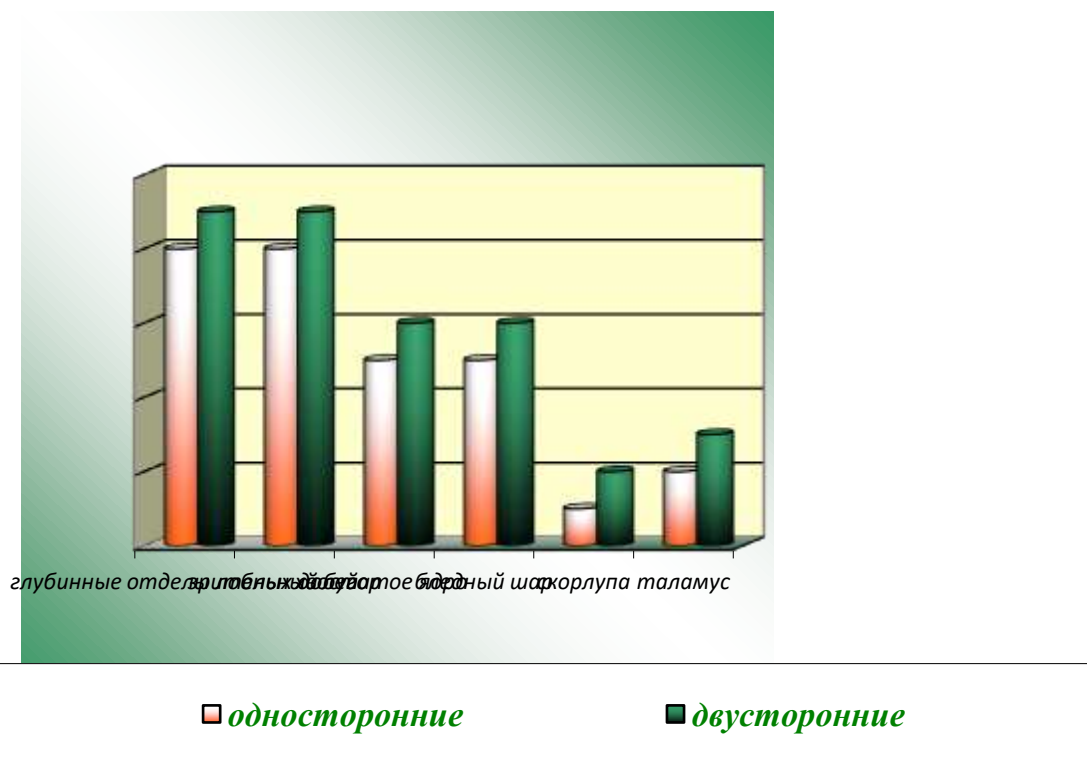
In patients with bilateral LA lesions in the *caudate nucleus*, cognitive impairments were more pronounced than in unilateral localization, mnemonic and speech impairments, visual attention and spatial functions disorders prevailed. Impairment of cognitive functions in patients with localization of PA foci mainly in the frontal lobes resembled a lesion of the caudate nucleus. In patients with bilateral LA

lesions in the white matter of the frontal lobes, neurodynamic and mnemonic disorders, expressive speech, executive and spatial functions disorders prevailed.

With the localization of subcortical PA foci in the thalamus, mainly on the right, neurodynamic disorders predominated in the

form of a decrease in concentration of attention, impaired verbal-logical thinking. In patients with bilateral localization of foci in the thalamus, mnemonic disorders, speech disorders, and executive function disorders were more often found.

Figure 3. Comparative analysis of the results of neuropsychological testing in comparison with unilateral and bilateral foci of a certain localization of leukoaraiosis in subcortical vascular dementia



According to the data obtained, the localization of subcortical LA foci is of great importance in the development of cognitive impairment in patients with vascular subcortical dementia. The most pronounced changes are noted in the defeat of the deep sections of the frontal lobes and the thalamus. Somewhat less pronounced, but quite distinct cognitive impairments were also found in lesions of the caudate nucleus and globus pallidus. PA foci with predominant localization in the shell region had a lesser effect on cognitive functions in patients with subcortical dementia. With the defeat of the thalamus, neurodynamic, speech and mnemonic disorders prevailed. A feature of the defeat of the thalamus is a pronounced impairment of

attention associated with the defeat of its pillar.

The results of this study indicate that the basis of cognitive impairment in vascular subcortical dementia is violations of regulatory and neurodynamic functions caused by damage to predominantly subcortical-frontal connections. Further deepening of the cognitive defect and the progression of dementia occur mainly due to regulatory disorders, which reflects a more pronounced dysfunction of the frontal lobes. The severity of cognitive impairment in subcortical dementia depends on the prevalence and regional distribution of PA, and the localization of subcortical PA foci. The nature of cognitive impairments and their relationship with diffuse damage to the subcortical and frontal white

matter and damage to the deep sections of the frontal lobes, caudate nucleus and thalamus is explained by the defeat of the fronto-striato-pallido-thalamocortical circles and dissociation of the frontal lobes, basal ganglia and thalamus.

Comparative analysis of neuropsychological testing indicators revealed certain differences between groups of patients with different localization of post-stroke foci *in the right hemisphere of the brain*. The presence of post-stroke foci in the white matter of the hemisphere leads to the aggravation of cognitive impairment, to a greater extent, with the localization of post-stroke changes in the frontotemporal region and in the mediobasal regions of the hemisphere.

In patients with localization of post-stroke foci *in the fronto-parietal region* of the right hemisphere, mnemonic, speech and orientation disorders prevailed. In patients with localization of post-stroke foci *in the frontotemporal region and in the mediobasal regions*, pronounced mnemonic disorders, disorders of optical-spatial gnosis, executive functions, and disorders of visual-figurative thinking were more often found. With the localization of lesions *in the basal nuclei* of the hemisphere, operational disorders, mnemonic disorders in the form of a decrease in the activity, strength and selectivity of memorizing words and violations of spatial functions prevailed.

Thus, in patients with localization of post-stroke foci in the right hemisphere of the brain, neurodynamic, mnemonic disorders and operational disorders prevailed. All patients were found to have neurodynamic disorders in the form of a decrease in concentration, impaired verbal-logical thinking. Mnemonic disturbances manifested themselves during the performance of tasks requiring sequential memorization and reproduction (words, phrases).

Speech disorders in right-hemispheric foci were manifested by verbosity, the use of explanatory phrases or their approximate

synonyms, as a result of which the patients' speech lost its meaningful characteristics.

Operational disorders in patients with right-hemispheric localization of foci were manifested by a violation of praxis. The most pronounced cognitive impairments were noted in the localization of post-stroke changes in the frontotemporal region and in the mediobasal parts of the hemisphere. Somewhat less pronounced, but quite distinct cognitive impairments were found in lesions of the basal ganglia and fronto-parietal region of the right hemisphere.

Comparative analysis of neuropsychological testing indicators revealed certain differences between groups of patients with different localization of post-stroke foci *in the left hemisphere of the brain*.

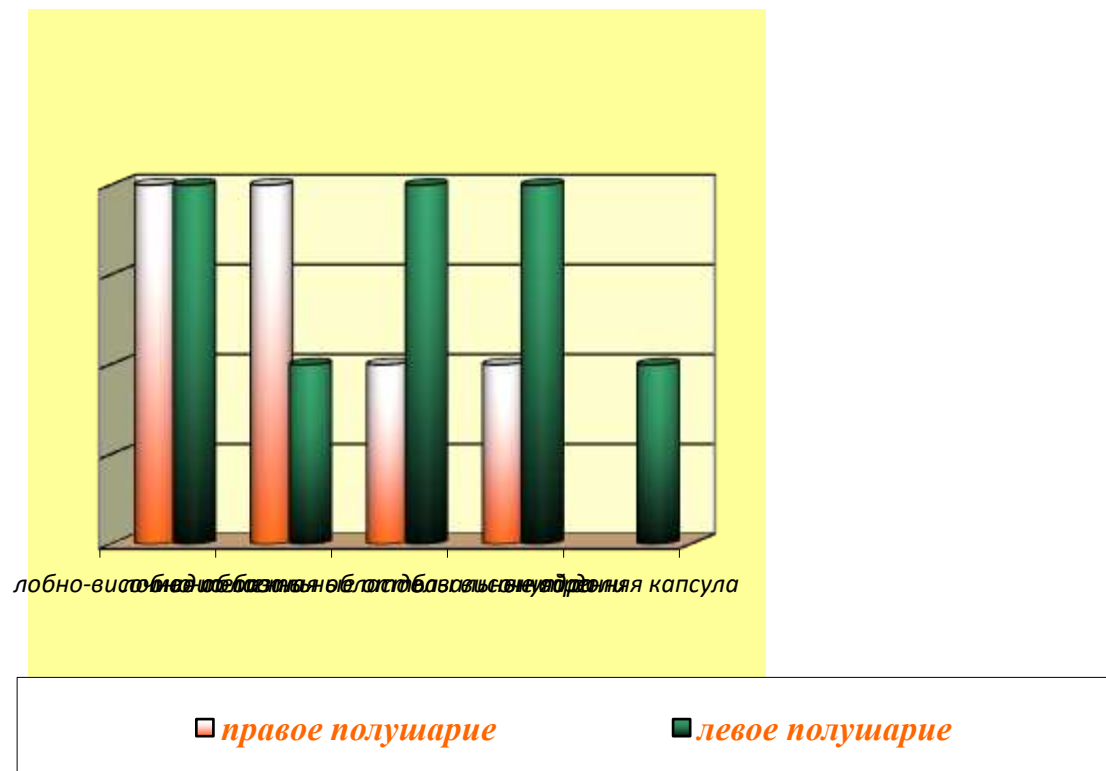
In patients with localization of post-stroke foci *in the fronto-parietal region* of the left hemisphere, orientation disorders, operational disorders and disorders of spatial functions predominated.

In patients with localization of post-stroke lesions *in the frontotemporal region and in the mediobasal regions*, mnemonic and speech disorders, disorders of optical-spatial gnosis, executive functions, and disorders of visual-figurative thinking were more often found.

With localization of foci *in the basal nuclei* of the hemisphere, pronounced operational disorders and mnemonic disorders, disorders of visual attention, executive functions, and optical-spatial gnosis prevailed.

Thus, the presence of post-stroke foci in the white matter of the left hemisphere leads to the aggravation of cognitive impairment, to a greater extent, with the localization of post-stroke changes in the mediobasal regions of the temporal lobe, basal ganglia and the frontotemporal region of the hemisphere, less pronounced, but quite distinct impairments were determined with the localization of post-stroke foci in the fronto-parietal region of the hemisphere or in the internal capsule (Figure 4).

Figure 4. Comparative analysis of the results of neuropsychological testing in comparison with the distribution of leukoariosis in various parts of the right and left hemispheres in post-stroke vascular dementia



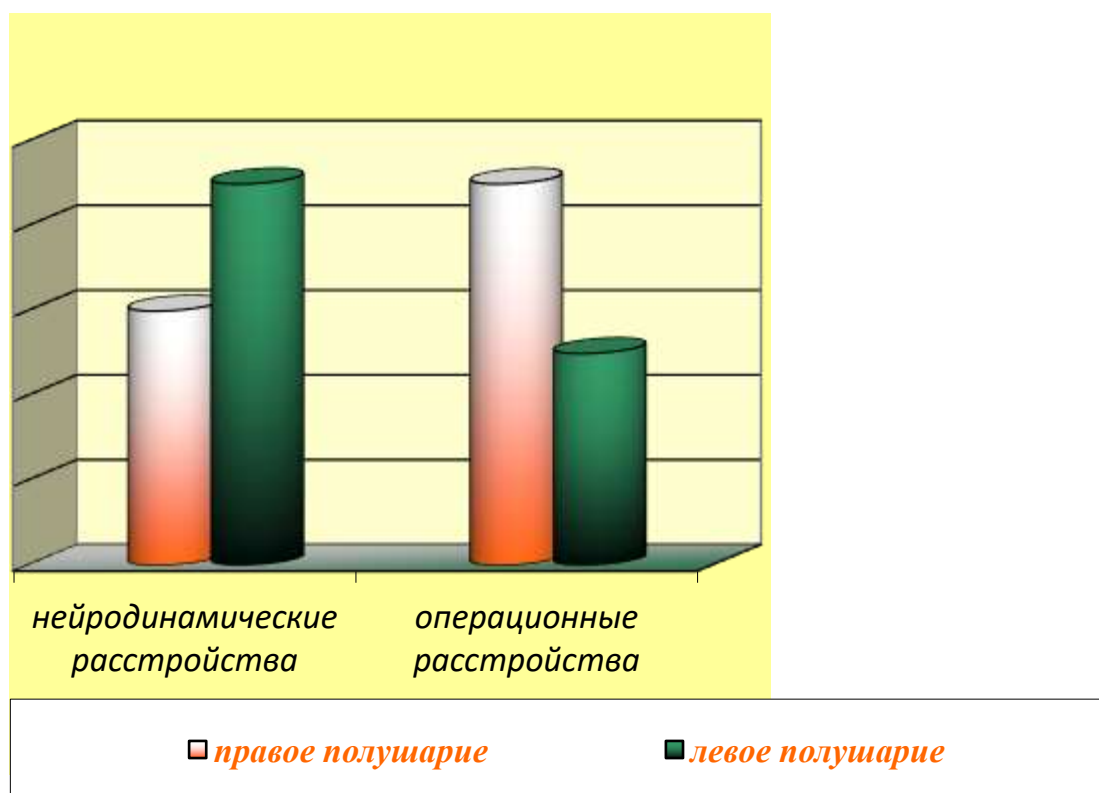
To determine the clinical significance of the affected cerebral hemisphere, a comparative analysis of the parameters of neuropsychological testing was carried out between groups of patients who had post-stroke foci of a certain localization, but located in different hemispheres.

A comparative neuropsychological study showed that in patients with localization of post-stroke foci *in the left hemisphere*, neurodynamic disorders predominated (decreased concentration of attention, difficulties in completing tasks in tests with time limits, difficulty entering a task, rapid exhaustion in performing tasks), memory disorders associated with a decrease in the activity and selectivity of memorization or a violation of attention, a violation of reproduction and recognition. With the localization of foci in the left hemisphere, a violation of the regulatory role of speech, impoverishment of speech production, a decrease in speech initiative, and speech attention were clearly manifested. Violations of understanding of logical and grammatical

structures, difficulties in choosing words, verbal paraphasias were revealed.

Neuropsychological disorders in patients with *right-sided localization of post-stroke foci* were qualitatively different from the disorders detected in patients with left-sided localization of foci — operational disorders were more often found in the form of praxis disorders, which appeared as difficulties in performing actions, deautomatization of motor skills, and optical-spatial gnosis. In the study of memory in patients with right-sided localization of foci, mnemonic disorders were found in the form of a decrease in the activity, strength and selectivity of memorizing words and images. Violations of executive functions were noted, manifested by a violation of planning, violations of the execution of tests that provide for a time limit. Speech disorders in right hemispheric foci were manifested by verbosity, the use of explanatory phrases or their approximate synonyms. However, regardless of the side of the lesion, the patients' speech lost its meaningful characteristics (Figure 5).

Figure 5. Comparative analysis of impaired functions in comparison with the distribution of leukoaraiosis of the right and left hemispheres in subcortical vascular dementia



Conclusion

1. In case of vascular subcortical dementia, in case of predominance of intellectual-mnemonic disorders in the structure of dementia, it is advisable to prescribe cortexin. If in the structure of dementia, along with cognitive impairment, functional and motor disorders are expressed, it would be reasonable to prescribe complex therapy with cortexin and gliatillin. In post-stroke dementia, both in the presence of intellectual-mnemonic disorders, and functional and motor disorders, the appointment of gliatillin is preferable. The latter, with post-stroke moderate dementia, improves motor, behavioral and household activity in patients with post-stroke dementia, to a greater extent than with mild dementia.

2. Comparative analysis of neuroimaging changes in patients with vascular subcortical dementia revealed certain differences. The total area of the LA and the area of the periventricular LA were significantly higher in patients with moderate dementia. In patients with moderate dementia, the LA area in the subcortical white matter, in the area adjacent to the anterior horn (frontal LA), and in the anterior regions of the brain

(anterior LA) was significantly higher than in patients with mild dementia.

All patients with vascular subcortical dementia had various types of periventricular and subcortical leukoencephalopathy (LA). The incidence of subcortical LA was significantly higher in the group of patients with moderate dementia. In the group of patients with mild dementia, subcortical LA was represented with approximately equal frequency by small, partially confluent lesions. Most often, subcortical foci were localized in the basal ganglia, deep sections of the frontal lobes, periventricular zone, less commonly, foci were detected in the thalamus, pons, semioval center.

3. An increase in the severity of cognitive deficit in patients with vascular post-stroke dementia is significantly associated with the localization of post-stroke focal changes in the fronto-temporal-occipital region of the left hemisphere, in the area of the thalamus and basal nuclei of both hemispheres of the brain; with the prevalence and severity of subcortical leukoencephalopathy in the frontal and anterior parts of the brain, basal ganglia and thalamus, and in patients with subcortical vascular dementia -

with localization of subcortical foci of leukoaraiosis in the region of the basal ganglia and thalamus, as well as with bilateral localization of subcortical foci of leukoaraiosis; with the prevalence and severity of subcortical leukoaraiosis in the anterior parts of the brain.

Literature

1. Muradimova, A. R., & Akhmedova, F. Sh. (2019). Nursing care of patients with hemorrhagic stroke. In *Innovation in Medicine* (pp. 188-192).
2. Muradimova, A. R., Usmanova, D. D., & Sadikov, U. T. (2020, October). Crossing parallels: vascular dementia and coronary heart disease. in *scientific and practical conference with international participation "Actual problems of pathophysiology"* (Vol. 28, p. 85).
3. Muradimova, A. R. (2019). Clinical and neurological features of the course of vascular epilepsy, prognosis and treatment. In *Innovation in Medicine* (pp. 178-182).
4. Akhmedova, F. Sh., Akhmedova, E. A., Muradimova, A. R., & Abduzhapparova, N. E. (2019). Cognitive impairments in post-traumatic encephalopathy. In *Innovation in Medicine* (pp. 166-173).
5. Muradimova, A. R. (2019). Clinical and diagnostic aspects and modern approaches to the treatment of vascular dementia. In *Innovation in Medicine* (pp. 185-188).
6. Usmanova, D. D., Muradimova, A. R., & Ashuraliev, I. M. (2019). Neurotrophic blood proteins and their correlations with vascular risk factors in patients with discirculatory encephalopathy complicated by vascular dementia. *Editorial Board*, 12.
7. Muradimova, A. R. (2019). Clinical and neurological features of the course of vascular epilepsy, prognosis and treatment. In *Innovations in medicine. Materials of the I International Scientific and Practical Conference-Makhachkala, 2019.-Vol. II.-232 p.* (p. 178).
8. Rashidovna, AM, & Usmanova, DD Vascular dementia: neuroimaging aspects. *Biomedicine va amalyot journals*, 200.
9. Muradimova, A. R. (2019). Neurophysiological aspect of metabolic therapy of chronic cerebral ischemia. In *Innovation in Medicine* (pp. 192-197).
10. Muzaffar, G. (2023). Features of Reactive Psychosis in Schizophrenia. *Research Journal of Trauma and Disability Studies*, 2(1), 44-49.
11. Muzaffar, G. (2023). Modern Concepts About Schizophrenia. *Eurasian Medical Research Periodical*, 16, 37-41.
12. Гуломқодиров, М., & Машрапов, Ж. (2022). ЭМПИРИЧЕСКИЙ ПОИСК ВЗАИМОСВЯЗИ КОГНИТИВНОГО ФУНКЦИОНИРОВАНИЯ И ОБЩЕКЛИНИЧЕСКОЙ КАРТИНЫ У БОЛЬНЫХ ШИЗОФРЕНИЕЙ. *Theoretical aspects in the formation of pedagogical sciences*, 1(5), 221-223.
13. Долимова М.А., Аграновский М.Л., Солиев Д.М., Гуломқодиров М.М. (2022). РОЛЬ ПОДДЕРЖИВАЮЩЕЙ ТЕРАПИИ В СРАВНИТЕЛЬНОЙ ЭФФЕКТИВНОСТИ КАЧЕСТВА И СТРУКТУРЫ РЕМИССИЙ ПРИ РЕЦИДИВНОЙ ШИЗОФРЕНИИ. *Искусство медицины. Международный медицинский научный журнал*, 2 (1).
14. Гуломқодиров, М. (2021). АФЪЮНГА ҚАРАМЛИК ХОСИЛ БУЛИШ ДИНАМИКАСИ ВА ХУСУСИЯТЛАРИ. *Интернаука*, (20-7), 23-25.
15. Аграновский, М. Л., Гуломқодиров, М. М., Далимова, С. А., & Муминов, Р. К. (2022). АНАЛИЗ ДАННЫХ ОТДАЛЁННОГО КАТАМНЕЗА ПРИ ШИЗОФРЕНИИ С РЕМИТТУРУЮЩИМ ТИПОМ ТЕЧЕНИЯ. *Экономика и социум*, (6-2 (97)), 285-288.
16. Аграновский, М. Л., Гуломқодиров, М. М., Муминов, Р. К., & Далимова, С. А. (2022). ОТДАЛЕННЫЙ ЭТАП ШИЗОФРЕНИИ С РЕМИТТУРУЮЩИМ ТИПОМ ТЕЧЕНИЯ И РАССТРОЙСТВ

- ШИЗОФРЕНИЧЕСКОГО СПЕКТРА. *Экономика и социум*, (6-2 (97)), 289-292.
17. Фуломқодиров, М. (2021). ЮРАК-ҚОН ТОМИР КАСАЛЛИКЛАРДАГИ ДЕПРЕССИЯ ХОЛАТИНИ ТАШХИСЛАШ ВА ДАВОЛАШНИ ТАКОМИЛЛАШТИРИШ. *Интернаука*, (17-4), 61-62.
18. Zokirov M., Mukhammadjonov, O. (2022). Cognitive Impairments in Patients with HIV-Associated Encephalopathy. *Central asian journal of medical and natural sciences*, 3(2), 401-405.
19. Zokirov, M. M., & Mukhammadjonov, O. (2022). Cognitive impairment in patients with Parkinson's disease and optimization of its treatment. *Eurasian Scientific Herald*, 7, 177-180.
20. Зокиров, М., & Туланбоева, С. (2022). Когнитивные нарушений у пациентов с ВИЧ-ассоциированной энцефалопатией. *Barqarorlik va yetakchi tadqiqotlar onlayn ilmiy jurnali*, 68-73.
21. Muzaffar, Z. (2022). Literature reviews on nervous system damage during hiv infection. *Barqarorlik va yetakchi tadqiqotlar onlayn ilmiy jurnali*, 2(9), 141-147.
22. Muzaffar, Z. (2022). Correction of cognitive disorders in patients with hiv encephalopathy. *Web of Scientist: International Scientific Research Journal*, 3(12), 402-411.
23. Muzaffar, Z. (2022). Psychological State in Patients with HIV Infection. *Amaliy va tibbiyot fanlari ilmiy jurnali*, 1(6), 52-56.
24. Зокиров, М., & Мадмаров, Д. (2022). Корреляция ээг картины головного мозга и когнитивного статуса у пациентов с эпилепсией. *Theoretical aspects in the formation of pedagogical sciences*, 1(5), 227-230.
25. Зокиров, М. (2021). *Medical sciences. scientific ideas of young scientists*, 21
26. Зокиров, М. (2022). Анализ когнитивных нарушений у пациентов с ВИЧ-ассоциированной энцефалопатией. *Barqarorlik va yetakchi tadqiqotlar onlayn ilmiy jurnali*, 2(10), 251-260.
27. Muhammadjonov, O., & Zokirov, M. 2-toifa qandli diabet bilan og'rigan bemorlarda yurak-qon tomir kasalliklarining xavf omillarining tarqalishi. *Студенческий вестник Учредители: Общество с ограниченной ответственностью "Интернаука"*. *Тематическое направление: Other social sciences*, 53-54.
28. Зокиров М. Коррекция когнитивных нарушений у больных с ВИЧ-ассоциированной энцефалопатией. *Дж. Теор. заявл. науч.* 2021, 7, 62-66. [[Академия](#) [Google](#)] [[Перекрестная ссылка](#)]