



OBLIQUE MRI OF NORMAL STRUCTURES

1 Ghaidaa Hassan Thamer shalal	Al-Karkh University of Science, College of Science, department Medical Physics/ ghaidaahthamer@gmail.com
2 Abbas Fadhil Muhammad Abdullah	al mustaqbel university Department of Medical Physics/ bsbwsy564@gmail.com
3 Diao Mohsen Muhammad Ali Youssef	Al-Karkh University of Science, College of Science, Medical Physics/ dyaalywsf588@gmail.com
4 Sattat jabbar hasan Hadad	Al-Karkh College of Science/ Department of Medical Physics/ sattar.hasan@kus.edu.iq
5 Narges Muhammad Jassim Aweez	Dhi Qar University, College of Science/Department of Medical Physics/ Narjesn081@gmail.com

ABSTRACT

Magnetic resonance (MR) imaging allows freedom in choosing oblique planes of section and rotation of image plane with respect to frequency encoded (F) and phase-encoded (P) dimensions. A general method is described for understanding geometric relationships between the fixed magnetic coordinate system, patient position and the flexible observers coordinate system. Oblique planes of section are clinically useful in studying organs with an axis symmetry that is oblique to magnet coordinate system, such as the heart. Rotation of image plane can be used to move motion artifacts away from anatomic regions of interest, such as the liver and spine. Appropriate use of oblique section and image rotation can improve MR image quality and diagnostic value of the patient study.

Keywords: Magnetic resonance, image plane, heart

Introduction

One of the many advantages of MRI is the ability to image in any oblique plane such oblique imaging requires gradient magnetic field along oblique trajectories .To generate such oblique gradients however we do not require any additional hardware. considering the gradients as vector we can see how turning on two or three gradients simultaneously will generate an obliquely oriented gradient magnetic field it is the magnitude of each component that determines the orientation of the gradient so we just adjust the amount of current pumped into each gradient coil to generate the desired oblique gradient magnetic field. The direct acquisition of sectional images in any desired plane is an inherent advantage of magnetic resonance imaging (MRI) over computed tomography (CT). Because of the orthogonal arrangement of the

three-gradient coil, most MRI systems are capable of obtaining images in standard axial, coronal, and sagittal orientation. Images of oblique planes that are rotated around one of the three standard orthogonal axes can be generated without hardware modification by simultaneous application of two orthogonal gradient fields during the three phases (slice selection, phase encoding, and signal read-out) of Fourier imaging [1]. Such slices may be useful in evaluating certain anatomic structures, organs, and lesions with oblique topographic orientation. We describe a method of generating MR images in oblique planes by a simple modification of an existing spin-echo pulse sequence program and assess its use in demonstrating various normal anatomic structures .Oblique plane has become very common in MRI because the most diagnostically useful imaging plane are not always perpendicular to the X, Y, and Z axes or parallel to each other. Oblique image is production of images which lie between the conventional X, Y, and Z axes. MRI, there is no degradation of image quality or loss of spatial resolution as compared to reformatted CT images [2]. In addition, special patient positioning [3] is avoided. With the capability of oblique imaging, MRI gains much of the multiplanar flexibility of sonography. The use of oblique high-resolution images

holds promise in selected applications, and may facilitate the assessment of certain organs. It seems , that oblique MRI can be useful in examining certain areas of, the spine and skeletal system (figs. 1.1 and 1.2). Surface coil images parallel to the vertebral end-plates could significantly add to the value of MRI in diagnosing lumbar disk disease [4].

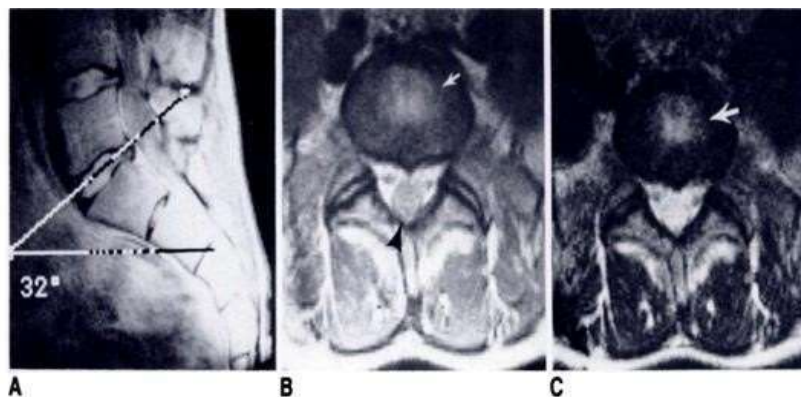


Figure 1.1 Lumbar spine with surface coil. A, Preliminary sagittal scan; 1.8 sec TR, 35 msec TE. B and C, Oblique scans through L4-L5 intervertebral disk; 2.0 sec TR, 45 msec TE (B) and 2.0 sec TR, 100 msec TE(C); 17 mm scan time. Nucleus pulposus (arrow); dural sac (arrowhead).

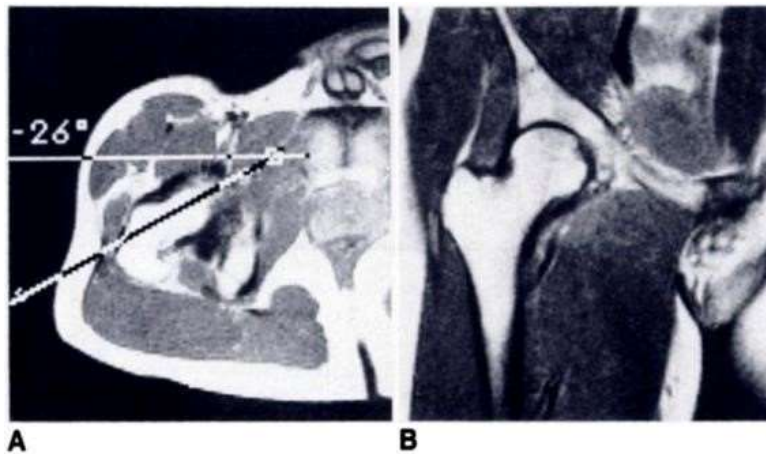


Figure 1.2 Right proximal femur. A, Axial orientation; 0.6 sec TR, 30 msec TE. B, Oblique scan; 0.8 sec TR, 45 msec TE, 7 mm scan time. Greater trochanter and femoral neck and head in acetabulum are shown.

The assessment of the anterior cruciate ligament of the knee is another application for which oblique MR images have been proposed [5]. Oblique MRI offers the advantage of obtaining sectional images of the heart that better conform to the spatial orientation of this organ (fig. 1.3). This could improve the quantitative

assessment of regional and global ventricular function [6]. High-resolution images in oblique planes are also necessary for the proper longitudinal depiction of certain vessels such as the thoracic aorta or carotid bifurcation [7]. Finally, oblique images may prove useful in selected cases of mass lesion. They may better demonstrate the true extent of a lesion and its relation to adjacent structure

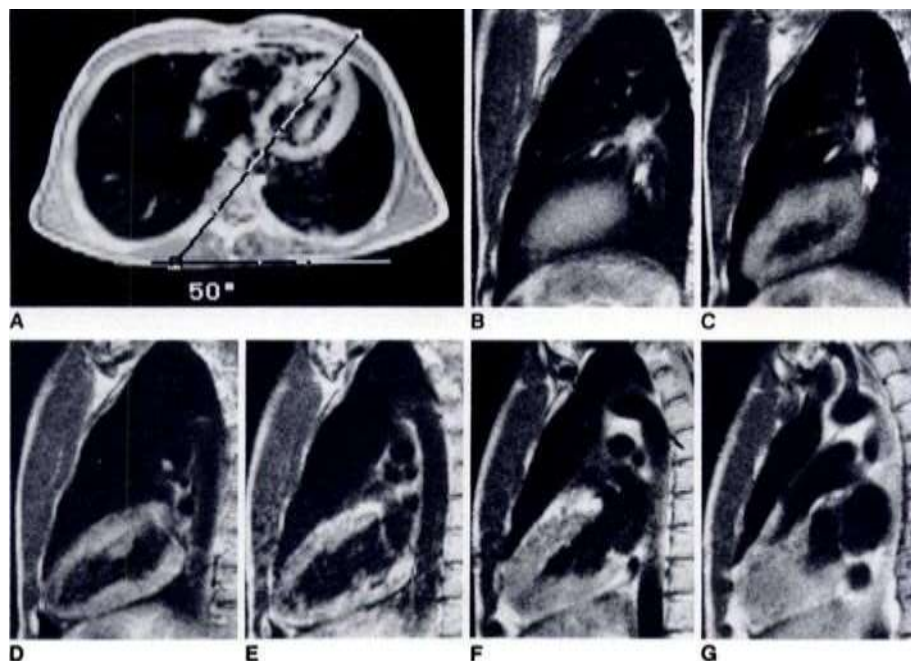


Figure 1.3 left. ventricle with cardiac gating; TA corresponds to 1 AR interval. A, Fast axial orientation; 35 msec TE, 4.4 mm scan time. B-G, Oblique scans parallel to interventricular septum at midheart level; 45 msec TE, 256 x 256

image matrix, 2 x 8.7 mm scan time. Images were combined from two separate multislice sequences, which were shifted by 10 mm in order to obtain contiguous cuts.

1.2 Aim of the study

1. To know the normal structure in oblique plane and compare with standard orientation to extract abnormalities.
2. To comparison between normal standard orientation and abnormal oblique orientation
3. Selecting the best and most accurate diagnosis helps doctors evaluate the image as well as reduce the time of examination

2.1 History of MRI

MRI technique was a major breakthrough in 1977 in imaging technology. In an MRI, the subject is placed on a moveable bed that is inserted into a giant circular magnet. It is a non-invasive technique that does not involve exposure to radiation. It is usually painless medical test that helps physicians diagnose and treat medical conditions. MRI uses a powerful magnetic field, radio frequency and a computer to produce detailed pictures of organs, soft tissues, bone and virtually all other internal body structures. The images can then be examined on a computer monitor.

Magnetic Resonance Imaging was broadly introduced to the scientific community in 1973 when Paul C. Lauterbur published images representing the Nuclear Magnetic Resonance response of hydrogen nuclei in a pair of water-filled glass capillaries [8]. One-dimensional (1-D) projections of this response were first obtained through a procedure that involved applying static magnetic field gradients to the sample, mapping NMR frequency onto source position. A series of 1-D projections, acquired along different gradient directions, were then combined to reconstruct a two-dimensional image as illustrated in Fig. (4)

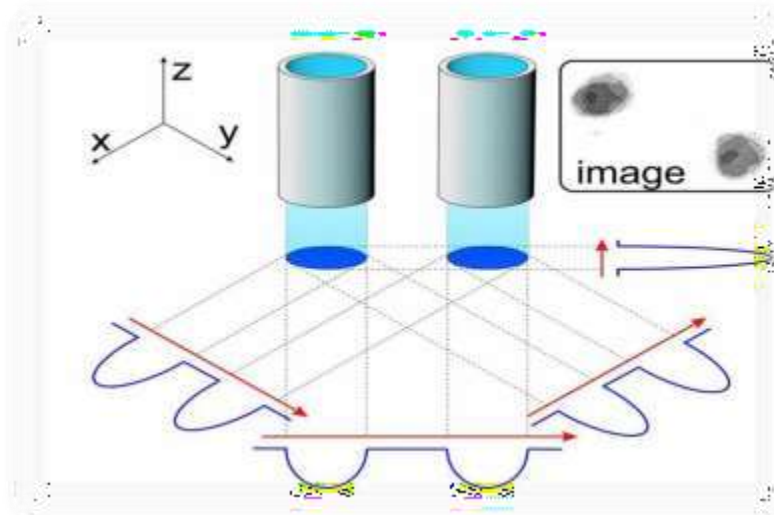


Figure 2.1 Principle underlying the first MR imaging experiment performed by P.C. Lauterbur [8].

Two objects (water-filled capillaries) aligned with the z-axis are shown, along with their projection onto the x-y plane. Magnetic field gradients applied along various

directions cause the NMR response to spread out in frequency, producing one-dimensional projections reflecting the distribution of water (blue curves). Multiple projections, acquired along different gradient directions (indicated by red arrows), are then combined to reconstruct a two dimensional image. Inset: Lauterbur's NMR image of two 1mm inner-diameter water-filled capillaries [8]. MRI (an abbreviation of magnetic resonance imaging) is an imaging modality that uses nonionizing radiation to create useful diagnostic images. MRI was initially called nuclear magnetic resonance (NMR) imaging after its early use for chemical analysis. The initial "nuclear" part was dropped about 25 years ago because of fears that people would think there was something radioactive involved, which there is not. NMR was discovered simultaneously by two physicists, Felix Bloch and Edward Mills Purcell, just after the end of the Second World War. Bloch trained in quantum mechanics and was involved with atomic energy and then radar countermeasures. At the end of the war, he returned to his earlier work in the magnetic moment of the neutron. Purcell was involved with the development of microwave radar during the war then pursued radio wave for the evaluation of molecular and nuclear properties. They received the Nobel Prize in Physics in 1952 for this discovery. MRI, the use of NMR to produce 2D images was accomplished by Paul Lauterbur, imaging water, and Sir Peter Mansfield who imaged the fingers of a research student, Andrew Maudsley in 1976. Maudsley continues to make a significant contribution to the development of MRI today. Raymond Damadian obtained human images a year later in 1977. Lauterbur and Mansfield received the Nobel Prize in Physiology or Medicine in 2003 for their development of MRI. This award was controversial in that the contributions of Damadian to the development of MRI were overlooked by the Nobel Committee .

2.2 Medical used of MRI

Medical imaging is the technique and process of creating visual representations of the interior of a body for clinical analysis and medical intervention, as well as visual representation of the function of some organs or tissues (physiology). Medical

imaging seeks to reveal internal structures hidden by the skin and bones, as well as to diagnose and treat disease. Medical imaging also establishes a database of normal anatomy and physiology to make it possible to identify abnormalities. Although imaging of removed organs and tissues can be performed for medical reasons, such procedures are usually considered part of pathology instead of medical imaging.

Uses

The development of the MRI scan represents a huge milestone for the medical world.

Doctors, scientists, and researchers are now able to examine the inside of the human body in high detail using a non-invasive tool.

The following are examples in which an MRI scanner would be used:

- anomalies of the brain and spinal cord
- tumors, cysts, and other anomalies in various parts of the body
- breast cancer screening for women who face a high risk of breast cancer
- injuries or abnormalities of the joints, such as the back and knee
- certain types of heart problems
- diseases of the liver and other abdominal organs
- the evaluation of pelvic pain in women, with causes including fibroids and endometriosis o suspected uterine anomalies in women undergoing reevaluation for infertility
- This list is by no means exhaustive. The use of MRI technology is always expanding in scope and use.

2.3 Risk of MRI

Because radiation is not used, there is no risk of exposure to radiation during an MRI procedure. However, due to the use of the strong magnet, MRI cannot be performed on patients with:

- Implanted pacemakers
- Intracranial aneurysm clips
- Cochlear implants

- Certain prosthetic devices
- Implanted drug infusion pumps

- Neurostimulators
- Bone-growth stimulators
- Certain intrauterine contraceptive devices; or
- Any other type of iron-based metal implants.

MRI is also contraindicated in the presence of internal metallic objects such as bullets or shrapnel, as well as surgical clips, pins, plates, screws, metal sutures, or wire mesh. If you are pregnant or suspect that you may be pregnant, you should notify your physician. Due to the potential for a harmful increase in the temperature of the amniotic fluid, MRI is not advised for pregnant patients. MRI generally is not advised for patients with epilepsy. If contrast dye is used, there is a risk for allergic reaction to the dye. Patients who are allergic to or sensitive to medications, contrast dye, iodine, or shellfish should notify the radiologist or technologist. MRI contrast may also have an effect on other conditions such as allergies, asthma, anemia, hypotension (low blood pressure), and sickle cell disease. There may be other risks depending upon your specific medical condition. Be sure to discuss any concerns with your physician prior to the procedure.

2.4 Advantage and disadvantage of MRI

2.4.1 Advantage

1. Ability to image without the use of ionizing x-ray, in contradistinction to CT scanning
2. Image may be acquired in multiple planes (axial, sagittal, coronal, or oblique) without repositioning the patient . CT images have only relatively recently been able to be reconstructed in multiple planes with the same spatial resolution
3. MRI images demonstrate superior soft tissue contrast as compared to CT scans and plain radiographs making it the ideal examination of brain , spine , joints , and other soft tissue body parts
4. Some angiographic images can be obtained without the use of contrast material , unlike CT or conventional angiography
5. Advance techniques such as diffusion , spectroscopy and perfusion allow for precise tissue characterization rather than merely “macroscopic” image
6. Functional MRI allows visualization of both active parts of brain during certain activities and understanding of the underlying networks

2.4.2 Disadvantage

1. MRI scans are more expensive than CT scans
2. MRI scans take significantly longer to acquire than CT and patient comfort can be an issue , maybe exacerbated by:
3. MR image acquisition is noisy compared to CT
4. MRI scanner bores tend to be more enclosed than CT with associated claustrophobia
5. MR images are subject to unique artifacts that must be recognized and mitigated against

6. MRI scanning is not safe for patients with some metal implants and foreign bodies. Careful attention to safety measures is necessary to avoid serious injury to patients and staff, and this requires special MRI compatible equipment and stringent adherence to safety protocols

2.5 Background and Motivation of Research

Most of the work reported on the subject of oblique MRI of the heart is performed by a combination of patient positioning and changing of a single gradient angle [9, 10, 11]. The patient has to be rotated in the scanner in a right or left anterior oblique position. This has the disadvantage of discomfort to the patient and decreased reproducibility. Moreover, when patient rotation is unsatisfactory he must be removed from the scanner for repositioning, which is time consuming. Improvement of software and hardware now allows for combined electronic axial rotation with reconstruction of specific viewing angles, as described in this report. Patient positioning can be omitted. Exact adaptation to individual variations is taken into account, enabling reliable assessment of cardiac function. Only in the four chamber view slight differences in orientation of plane section were observed between diastolic and systolic images of the same slice number, due to the anterior motion of the heart

in systole. While changing of multiple gradient angles is reported to affect data acquisition and image quality, our results did not show reduction of quality compared with our previous studies performed with a single gradient angle change and patient rotation. The flexibility of the method described is time saving, ensures high reproducibility and provides optimal correlation with LV angiography and twodimensional echocardiography as a solid base for investigation of cardiac anatomy and function, and eventually tissue characterization.

Sagittal-oblique technique clearly shows partial rupture because its' double angulation follows the specific course of the patient's ligament, due to approximate orientation of the external rotation of the foot. The advantages of this technique were described in MR studies of the knee after ligamentoplasty [12, 13, 14].

In assessment of the location of ACL partial rupture (upper attachment, middle part, lower attachment) both flexion technique and sagittal-oblique technique showed the same results, confirming lower attachment as the most common site of ACL partial rupture.

The exiting lumbosacral spinal nerve root passes obliquely through the intervertebral foramen in an inferior-ventral direction [15, 16]. Therefore, axial, sagittal, and coronal MRI may not precisely demonstrate the spinal nerve root in the extraforaminal region. Conventional foraminal MRI is taken at a right angle to the foramen; thus, foraminal MRI comprises oblique sagittal images. In contrast, our oblique MRI was taken parallel to the foramen and close to the oblique coronal plane. Oblique lumbar MRI was based on the radiological anatomy of the spinal nerve roots. Our findings suggest that oblique MR images can demonstrate foraminal and extraforaminal regions [17].

3.1 Methodology of Oblique MRI

Technique MR images were obtained from normal volunteers after informed consent was given. All examinations were performed in "neutral" supine position. We used a whole-body MR imaging system (, Siemens) with a superconducting magnet operating at a static field strength of 1.5 T. The oblique images were acquired (and displayed) in a 256 x 256 matrix with two signal averages. The standard head coil was used for imaging of the orbit. The heart and femoral neck were imaged with the whole-body coil. A special surface coil [18] served as radiofrequency (RF-receiver antenna for the study of the lumbosacral spinal.). The generation of an MR image in an oblique plane that is rotated around one of the three standard imaging axes (axial, coronal, sagittal) necessitates obliquely oriented gradient fields. In this work, the oblique gradient fields ($G_{x'}$, $G_{y'}$, $G_{z'}$) were generated by the simultaneous application of two of the three standard orthogonal gradient fields (G_x , G_y , G_z) and are given by the following equations, which correspond to a rotation of the coordinate system by the angle ϕ):

$$G_{x'} = G_x \cos(\phi) - G_y \sin(\phi)$$

$$G_{y'} = G_x \sin(\phi) + G_y \cos(\phi)$$

$$G_{z'} = G_z$$

where X' is the direction of slice selection, Y' is the direction of phase encoding, and Z' is the direction of signal read-out. The three indices X' , Y' , and Z' are interchangeable. This means, for the clinical application, that the imaging plane can be rotated by the angle ϕ in three ways: (1) from axial toward coronal, (2) from sagittal toward axial, and (3) from coronal toward sagittal orientation. A translational shift of the rotated plane can be obtained by altering the frequency of the RF pulses. Figure 6 illustrates both the rotation (in this case around the z axis) and the translation along the X' axis of the imaging plane.

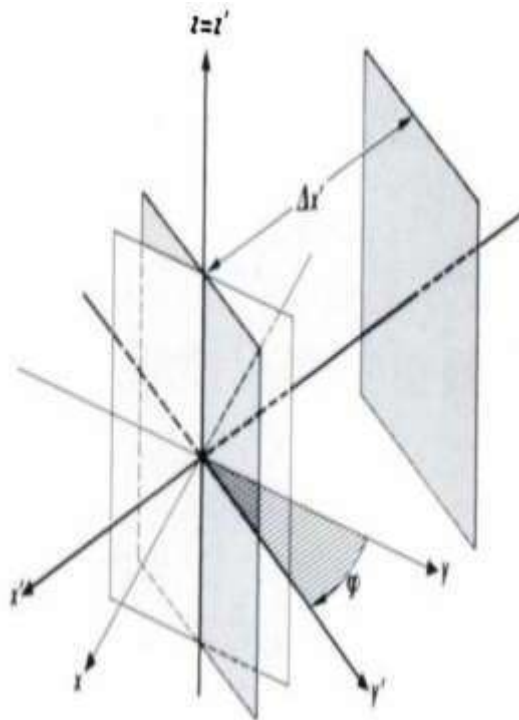


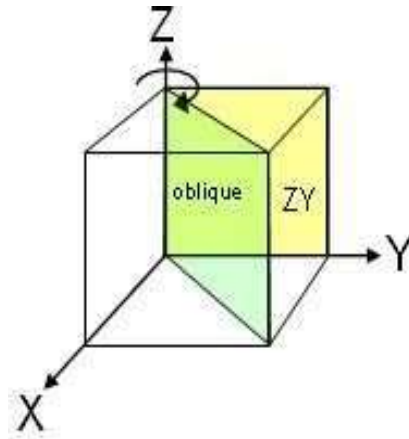
Figure 3.1 Generation of oblique MRI by simultaneous application of two orthogonal gradient fields (Gx,Gy) image plane is rotated around Z axis by angle phi .oblique (shaded) lies in rotated coordinate system with axes x`,y`,z`. Translation shift of rotated plane along x` axis can be obtained by altering frequency of RF pulses

Imaging of oblique planes can be accomplished by applying more than gradient during the slice selective 90 angle and 180 angle RF pulses. If a Y gradient is applied during slice selection an axial slice is defined . If Z and X gradient of equal magnitude are applied during selection an axial oblique slice is define the axial oblique slice would be at an angle of 45 degree to both the axial and Sagittal planes. oblique MRI. A plane or section not perpendicular to the xyz coordinate system, such as long and short axis views of heart oblique planes. Consider a clockwise rotation of the YZ plane by +45° about +z

$$\begin{bmatrix} X \\ Y \\ Z \end{bmatrix} = \begin{bmatrix} \cos\theta & \sin\theta & 0 \\ -\sin\theta & \cos\theta & 0 \\ 0 & 0 & 1 \end{bmatrix} \begin{bmatrix} X' \\ Y' \\ Z' \end{bmatrix} = \begin{bmatrix} 0.707 & 0.707 & 0 \\ -0.707 & 0.707 & 0 \\ 0 & 0 & 1 \end{bmatrix} \begin{bmatrix} X' \\ Y' \\ Z' \end{bmatrix}$$

For the slice selection gradient we have

$$\begin{bmatrix} X \\ Y \\ Z \end{bmatrix} = \begin{bmatrix} 0.707 & 0.707 & 0 \\ -0.707 & 0.707 & 0 \\ 0 & 0 & 1 \end{bmatrix} \begin{bmatrix} G_s \\ 0 \\ 0 \end{bmatrix} = \begin{bmatrix} 0.707G_s \\ -0.707G_s \\ 0 \end{bmatrix}$$



For the phase encoding gradient we have

$$\begin{bmatrix} X \\ Y \\ Z \end{bmatrix} = \begin{bmatrix} 0.707 & 0.707 & 0 \\ -0.707 & 0.707 & 0 \\ 0 & 0 & 1 \end{bmatrix} \begin{bmatrix} 0 \\ 0 \\ G_\phi \end{bmatrix} = \begin{bmatrix} 0 \\ 0 \\ G_\phi \end{bmatrix} \quad \begin{bmatrix} X \\ Y \\ Z \end{bmatrix} = \begin{bmatrix} 0.707 & 0.707 & 0 \\ -0.707 & 0.707 & 0 \\ 0 & 0 & 1 \end{bmatrix} \begin{bmatrix} 0 \\ G_\phi \\ 0 \end{bmatrix} = \begin{bmatrix} 0.707G_\phi \\ 0.707G_\phi \\ 0 \end{bmatrix}$$

For the frequency encoding gradient we have

$$\begin{bmatrix} X \\ Y \\ Z \end{bmatrix} = \begin{bmatrix} 0.707 & 0.707 & 0 \\ -0.707 & 0.707 & 0 \\ 0 & 0 & 1 \end{bmatrix} \begin{bmatrix} 0 \\ G_f \\ 0 \end{bmatrix} = \begin{bmatrix} 0.707G_f \\ 0.707G_f \\ 0 \end{bmatrix}$$

It should be apparent that this process can be applied to any number of rotations to get a any starting plane to any oblique location.

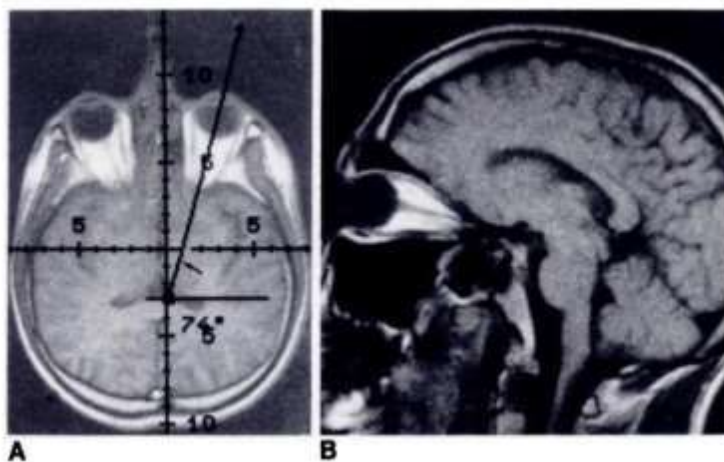


Figure 3.2 Optic nerve. A, Rapid axial view for orientation; 0.2 sec TA, 35 msec TE, 1.7 mm scan time. Left optic nerve lies in oblique plane that is rotated from coronal toward sagittal orientation by 74angle counter-clockwise. In addition, 8-mm translations shift toward left (arrow) of rotated plane is necessary in order to obtain oblique scan through left optic nerve. B, Resulting oblique scan; 0.5 sec TA, 45 msec TE, 4.3 mm scan time.

3.2 Patient numbers and Subjects Examinations

- ✦ Patient number and age: As shown in Table 3.1; the total number of patients is fifty-one patients according to the cases as follows:; 21 pelvis female MRI, 2 pelvis male MRI, 3 orbit female MRI, 3 orbit male MRI, 2 hip joint male MRI, 1 lumber spine female MRI, 1 lumber spine male MRI, 2 shoulder male MRI, 2 shoulder female MRI, 2 MRCP (abdomen) female, 8 knee joint male MRI, 3 knee joint female MRI and 1 cervical spine female. The age group ranges from 16 to 77 years.
- ✦ Duration: The data have been collected from (November 2018 to April 2019).
- ✦ Place of study: City of Medicine (Baghdad Teaching Hospital).
- ✦ Type of device: SIEMENS MRI Scan close type 1.5T
- ✦ Preparation of the patient: there is no special preparation for MRI scans. However, there are some important contra- indications:
 - ☒ If you have a pacemaker you cannot have an MRI
 - ☒ If you have metal in your body, (artificial joints ,metallic valves) you must let us know when scheduling. You may not be able to have the scan
 - ☒ If you are claustrophobic and your physician orders sedation, you must bring person who will drive you home
 - ☒ If you have had stents placed in your body within the last two months, you cannot have an MRI
 - ☒ Please let us know if you have a pacemaker , any metallic foreign bodies or if you are claustrophobic

3.3 Procedure of the examination

For all MRI scans , you will most likely change into a hospital gown. Our changing areas are private and there is a secure locker for your clothes . it is best, however, to leave valuable items at home. If you are wearing anything metallic, such as jewelry, dentures, eyeglasses, or hearing aids that might interfere with the MRI scan, we will ask you to remove them. You should not have your credit cards in your pockets during the scan because the MRI magnet can affect the magnetic strip on the card. Patients who are having a brain / head scan should not wear make- up as some brands contain metal.

- Please arrive 60 minutes before your appointment. This hour is needed to complete the registration process and assessment by the anesthesiology / nursing team

- When it is time for your exam, the technologist will escort you to the room , explain the exam, ask several questions and answer any questions you may have
- You will be required to remove any metallic object (jewelry, glasses, and clothing with zippers) and possibly put on a patient gown
- If your exam requires contrast, you will be asked complete a history form
- You will be placed on a table and guided into the machine
- During the exam, you will hear knocking or thumping sound. Sometimes this can be noisy, but earphones and music are available to help reduce the sound
- You can bring a music CD of your own to listen to during the exam
- You must lie still during the scan. There are microphones inside the machine so the technologist can communicate with you when needed
- The exam takes 30 minutes to 2 hours depending on the exam ordered
- When the exam is completed, the technologist will assist you off table and you may dress and leave
- Results will be forwarded to your physician , who will explain them to you
- If you were given a sedative, you will not be allowed to drive yourself home. Please make arrangements for transportation

Table 3.1: Patient number and age

No.	Age	Sex	Exame	Weight	No.	Age	Sex	Exame	Weight
1	44	m	knee	65	27	19	f	Pelvis	55
2	29	m	knee	55	28	16	f	Pelvis	43
3	21	m	knee	52	29	42	f	Pelvis	75
4	29	m	knee	66	30	56	f	Pelvis	80
5	26	m	knee	70	31	45	f	Pelvis	79
6	45	m	knee	75	32	54	m	Pelvis	85
7	22	m	knee	62	33	77	m	Pelvis	89
8	35	m	knee	60	34	61	f	lumber spine	79
9	39	m	knee	65	35	31	m	lumber spine	69
10	41	f	knee	65	36	12	f	shoulder	43
11	51	f	knee	70	37	44	m	shoulder	80
12	23	f	Pelvis	54	38	40	f	abdomen	78
13	45	f	Pelvis	62	39	35	f	orbit	79
14	53	f	Pelvis	74	40	55	f	orbit	88
15	25	f	Pelvis	55	41	35	m	orbit	78
16	44	f	Pelvis	76	42	37	m	orbit	82
17	33	f	Pelvis	67	43	39	m	orbit	87
18	47	f	Pelvis	78	44	39	m	hip	77

19	42	f	Pelvis	66	45	19	m	hip	57
20	45	f	Pelvis	78	46	42	m	shoulder	66
21	19	f	Pelvis	54	47	32	f	orbit	69
22	34	f	Pelvis	65	48	45	m	knee	80
23	39	f	Pelvis	76	49	18	f	Pelvis	55
24	30	f	Pelvis	67	50	39	m	cervical spine	78
25	49	f	Pelvis	78	51	49	f	abdomen	86
26	22	f	Pelvis	54					

* Device that uses for examinations is Siemens with 1.5 Tesla

4.1 Analysis of the results

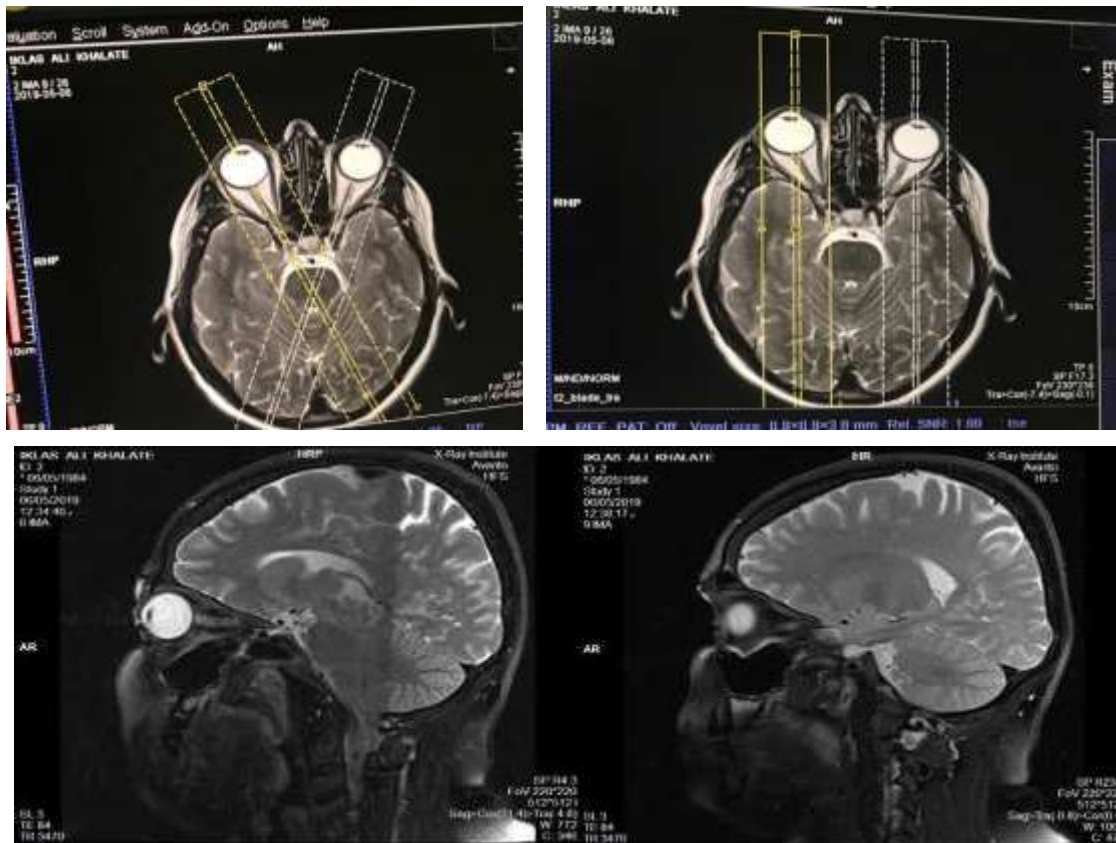
The results obtained were analyzed according to the type of examination as follows:

4.2 MRI of orbit

Sagittal oblique of orbit that show Optic nerve lesions - Optic nerve glioma and meningioma while Sagittal plane of orbit that no show accurately of optic nerve lesions

4.3 Characteristics of Sagittal oblique

1. Optics nerve
2. Superior rectus muscle
3. Inferior rectus muscle
4. Extra ocular muscle
5. Levator palpebrae superior muscle



A

B

Figure 4.1 (A) Sagittal oblique , (B) Sagittal plane.

Sagittal oblique MRI of orbit for evaluation entire optic nerve and image more accurate and high spatial resolution by reducing slice number therefore reduce acquisition time. While standard plane of orbit Sagittal plane that. Not useful for evaluation entire optic nerve and image not accurate and low spatial resolution because large numbers of slice and more artifact and taken more acquisition time.

4.4 MRI of Shoulder

Diagnostic value of angled oblique coronal images of the supraspinatus tendon for the detection of rotator cuff tears on MR imaging. The goal of this study was to evaluate the added value of coronal T2-weighted magnetic resonance imaging (MRI) of the supraspinatus tendon by comparison with a standard MRI protocol for the evaluation of the rotator cuff. The results of the specific MRI “cuff” protocol focusing on the supraspinatus are good, and helps facilitate interpretation of MRIs of the rotator cuff by nonspecialist radiologists, in particular of the supraspinatus muscle.

Characteristics of coronal oblique

1. Supraspinatus tendon
2. Infraspinatus tendon
3. Subacromial bursa

4. Acromioclavicular joint
5. Superior labrum and biceps anchor

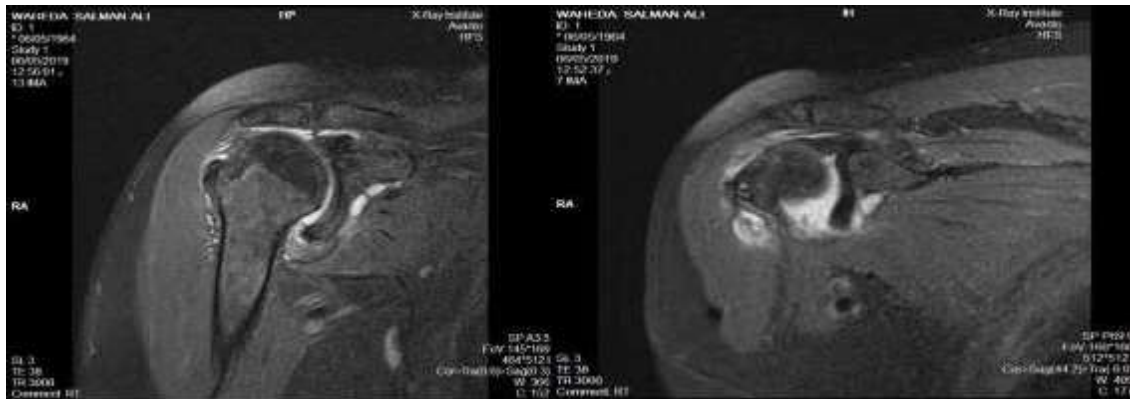
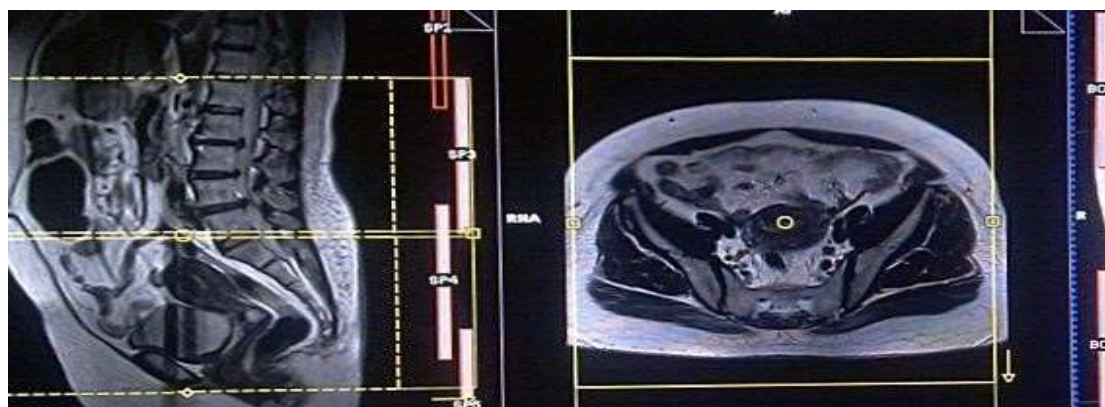

Figure 4.2 Right shoulder joint (A) coronal plane ,(B) coronal oblique plane

Coronal oblique of shoulder that evaluation of muscle and tendon and AC in the same time while the coronal plane only evaluation either muscle or tendon or AC that mean acquisition time reduce and high resolution by reducing number of slices. So the coronal oblique that characterizes is help doctors in diagnosis faster and accurate and therefore high resolution.

4.5 MRI of Pelvis

Pelvis female to demonstrate any pathology and congenital abnormalities of uterus. Thin-section oblique axial T2-weighted MRI can improve the success of conventional MRI for assessing USL endometriosis. However, further prospective studies are required to determine whether this additional MR sequence should be performed routinely in women with suspected pelvic endometriosis. Thin-section oblique axial magnetic resonance imaging (MRI) is useful in staging endometrial and cervical carcinomas but there are no data on its contribution to assessing deep endometriosis. We evaluated the contribution of this MRI technique to diagnosis of uterosacral ligament (USL) endometriosis.



A axial plane and **(B)** result of axia

B Figure 4.3 pelvis of female (A)

4.5.1 Axial plane of pelvis

A lot of numbers of slice and more artifacts therefore high acquisition time causes imaging low spatial resolution and less accurate and difficult to diagnosis by doctors.

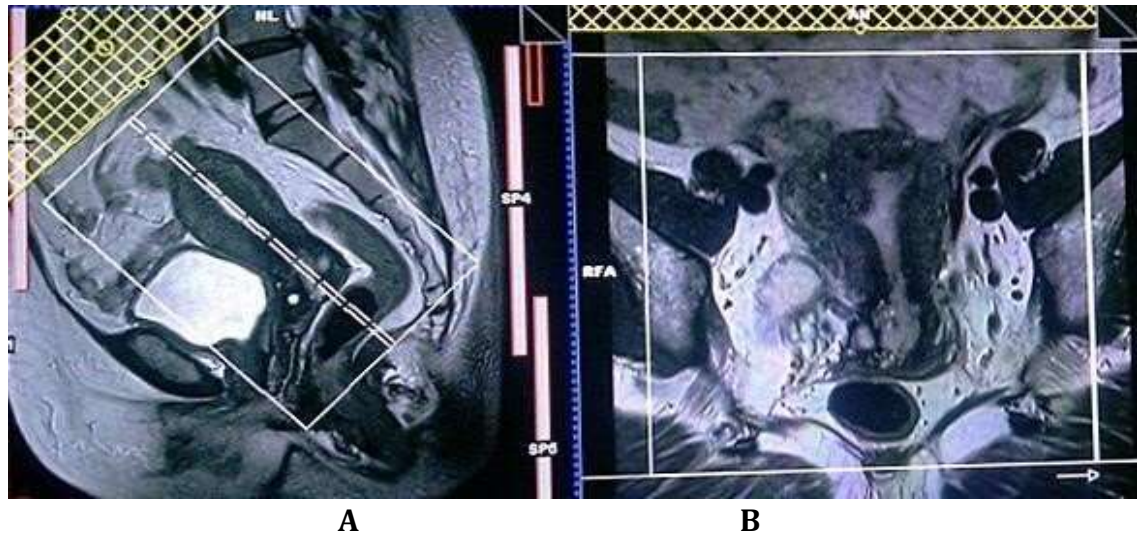


Figure 4.4 pelvis of female (A) axial oblique and (B) result of axial oblique.

4.5.2 Axial oblique of pelvis

less number of slice and reduce artifacts therefore low acquisition time causes imaging high spatial resend more accurate and easy to diagnosis by doctors.

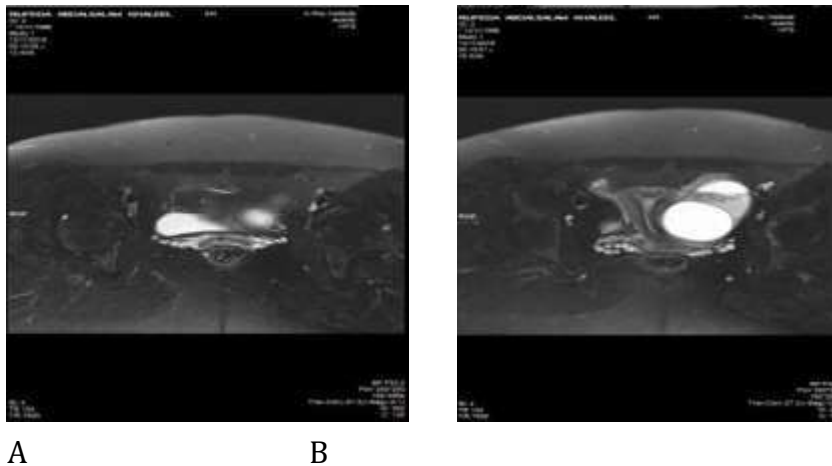


Figure 4.5 (A)axial oblique plane (B) axial plane.

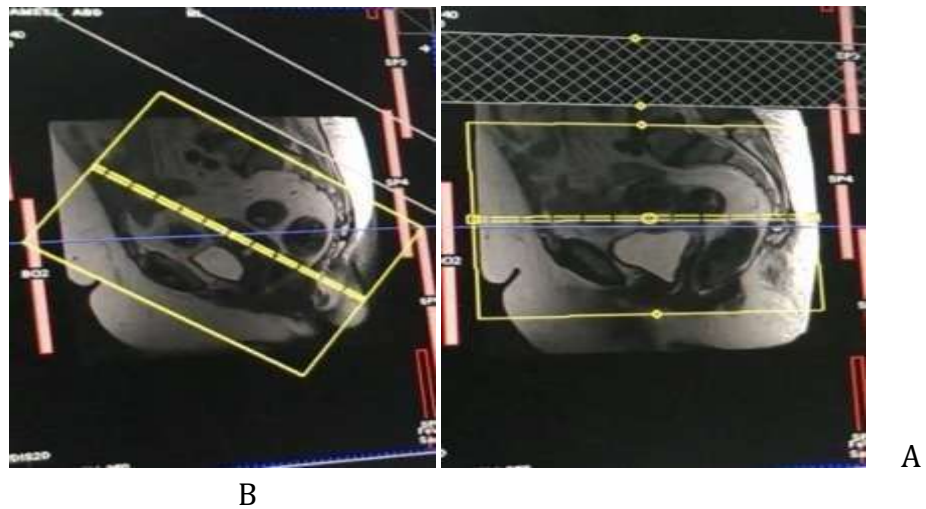


Figure 4.6 (A) axial plane and (B) axial oblique plane.

4.6 MRI of Cervical Spine

In this study, a new grading system for cervical foraminal stenosis is proposed, based on the oblique axial view. Oblique axial images provide much more information about the foramen than routine axial images because oblique images are oriented perpendicular to the course of the cervical neural foramen. Facet overgrowth, herniated lateral discs and unciniate process osteophytes that may induce foraminal stenosis are more easily detectable in the oblique axial view. So oblique axial image The oblique function of the cervical vertebrae is more accurate than the basic functions because the oblique function shows the appearance of the disc more than the basic position. Cervical oblique MRI can enable a more accurate surgical plan and

facilitate patient selection for surgery. Cervical oblique MRI could be useful for additional information and to predict the immediate prognosis of patients preoperatively.

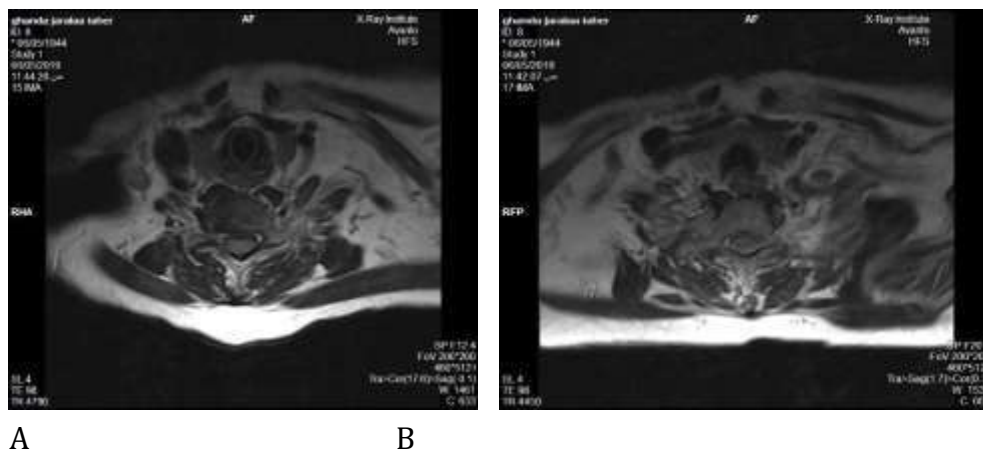


Figure 4.7 Cervical spine (A)axial oblique and (B) axial plane

4.7 MRI of the Knee joint

Our results showed that the evaluation of ACL rupture by oblique-sagittal MRI in addition to orthogonal MRI protocol is accurate and with high sensitivity and specificity values. It allows doctors in emergency departments to find abnormal images immediately with higher accuracy and more critically ill patients may benefit from the advantages of this imaging protocol. Therefore, training and using this method for emergency physicians or radiologists should be considered in this and other countries. Further studies are required to confirm our findings. On standard orthogonal sagittal MRI (it is difficult to visualize the ACL, while the ACL on the oblique sagittal MRI is obviously see.

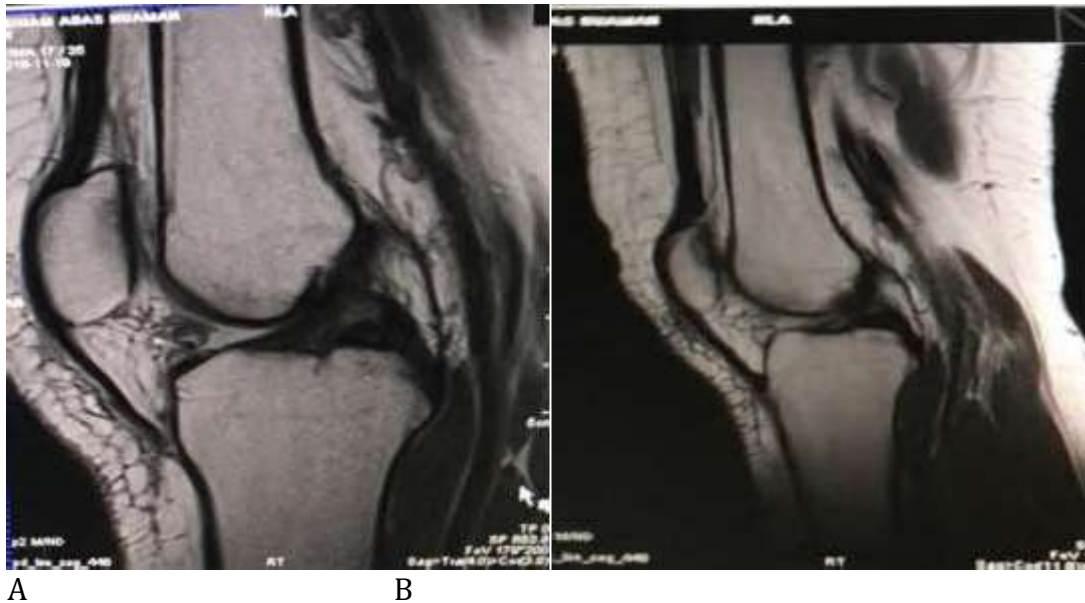

Figure 4.8 knee joint (A) sagittal oblique plane of knee and (B) sagittal plane of knee. Sagittal oblique of knee joint more accurate and high spatial resolution for evaluation ACL (anterior cruciate ligament) is better than Sagittal plane because number of slice lower and less artifact and reduce acquisition time

CONCLUSION

This project is made up of two main sections, covering use oblique slices design of MRI scanners in general and an use of slanted slides in specific medical conditions such as (Axial oblique of pelvis, Cervical Spine and Knee joint) investigation of MRI scanners. The first chapter introduced the topic and scope; the second chapter gave an overview of the function of oblique slices in MRI, based on oblique slices design and specific medical conditions investigations of MRI scanners.

- Dynamic of oblique slices has the potential to improve the quality of almost all of the applications of MRI that benefit from the signal-to-noise ratio increase.
- The use of oblique slices in medical diagnosis using magnetic resonance imaging has been activated, the results that the oblique plane reduces the number of slices and thus decreases the acquisition time.

- Compared to the previously adopted (normal; sagittal, coronal and transverse) imaging techniques, the use of oblique slices technique gives better anatomical details.

Recommendation:

- We recommend that more studies should be done to discover more advantage of the use of oblique slices designs.
- This study can be extended to include different parts of the body.
- A study focusing on the oblique slices of the heart can be achieved because of the urgent need to diagnose heart disease in high accuracy and in a relatively short time.

REFERENCES

1. Swenson, Todd M., and Christopher D. Harner. "Knee ligament and meniscal injuries. Current concepts." *The Orthopedic Clinics of North America* 26.3 (1995): 529-546.
2. Podobnik, Janez, et al. "3T MRI in evaluation of asbestos-related thoracic diseases-preliminary results." *Radiology and oncology* 44.2 (2010): 92-96.
3. Xu, Jie, et al. "The clinical value of combined use of MR imaging and multi-slice spiral CT in limb salvage surgery for orthopaedic oncology patients: initial experience in nine patients." *Radiology and oncology* 46.3 (2012): 189-197.
4. Wang, Xuhui, et al. "Comparison of CT and MRI in diagnosis of cerebrospinal leak induced by multiple fractures of skull base." *Radiology and oncology* 45.2 (2011): 91-96.
5. Lee, Kwansop, et al. "Anterior cruciate ligament tears: MR imaging-based diagnosis in a pediatric population." *Radiology* 213.3 (1999): 697-704.
6. Fruensgaard, S., and H. V. Johannsen. "Incomplete ruptures of the anterior cruciate ligament." *The Journal of bone and joint surgery. British volume* 71.3 (1989): 526-530.
7. Roychowdhury, Sudipta, et al. "Using MR imaging to diagnose partial tears of the anterior cruciate ligament: value of axial images." *AJR. American journal of roentgenology* 168.6 (1997): 1487-1491.
8. Noyes, F. R., et al. "Partial tears of the anterior cruciate ligament. Progression to complete ligament deficiency." *The Journal of bone and joint surgery. British volume* 71.5 (1989): 825-833.
9. Akins, E. William, et al. "Importance of imaging plane for magnetic resonance imaging of the normal left ventricle." *The American journal of cardiology* 56.4 (1985): 366-372.
10. Dinsmore, R. E., et al. "Magnetic resonance imaging of the heart: positioning and gradient angle selection for optimal imaging planes." *American journal of roentgenology* 143.6 (1984): 1135-1142.
11. Murphy, W. A., et al. "Oblique views of the heart by magnetic resonance imaging." *Radiology* 154.1 (1985): 225-226.
12. Roychowdhury, Sudipta, et al. "Using MR imaging to diagnose partial tears of the anterior cruciate ligament: value of axial images." *AJR. American journal of roentgenology* 168.6 (1997): 1487-1491.
13. Brandser, E. A., et al. "MR imaging of anterior cruciate ligament injury: independent value of primary and secondary signs." *AJR. American journal of roentgenology* 167.1 (1996): 121-126.

14. Falchhook, F. S., et al. "Accuracy of direct signs of tears of the anterior cruciate ligament." *Canadian Association of Radiologists journal= Journal l'Association canadienne des radiologistes* 47.2 (1996): 114-120.
15. Lawrance, J. A. L., S. J. Ostlere, and C. A. F. Dodd. "MRI diagnosis of partial tears of the anterior cruciate ligament." *Injury* 27.3 (1996): 153-155.
16. Jenis, Louis G., and Howard S. An. "Spine update: lumbar foraminal stenosis." *Spine* 25.3 (2000): 389-394.
17. Bae, Hack-Gun, et al. "Morphometric aspects of extraforaminal lumbar nerve roots." *Neurosurgery* 44.4 (1999): 841-846.
18. Zhang, Xiaoliang, Kamil Ugurbil, and Wei Chen. "Microstrip RF surface coil design for extremely high-field MRI and spectroscopy." *Magnetic Resonance in Medicine: An Official Journal of the International Society for Magnetic Resonance in Medicine* 46.3 (2001): 443-450.